

CytoSorbents™

4th
Edition



Case Series
and Case Reports

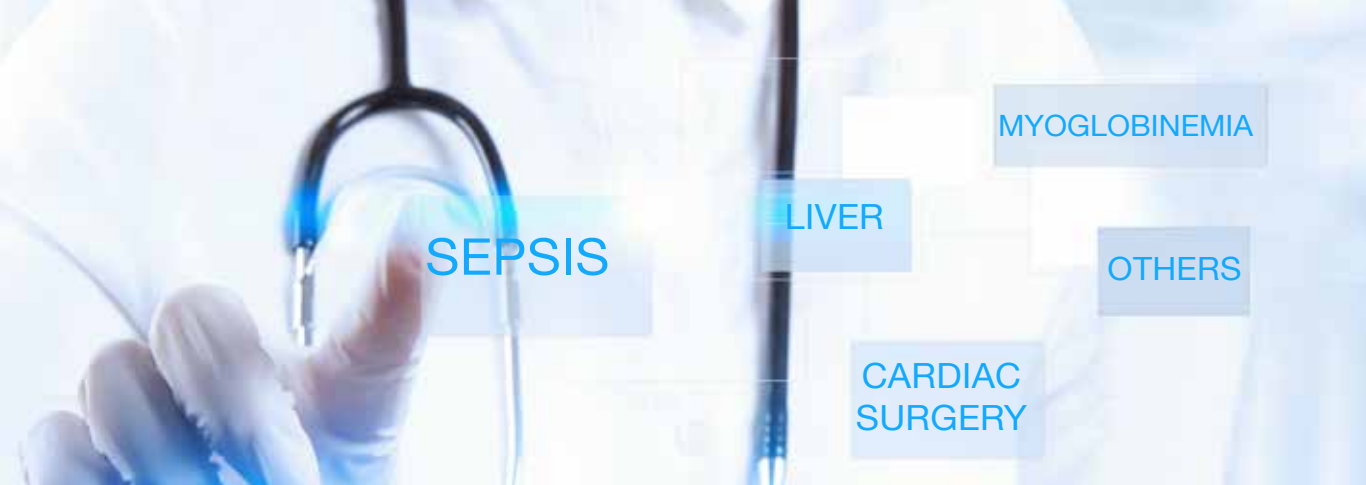

Table of contents

SEPSIS

A clinical experience of using extracorporeal cytokine adsorption device (CytoSorb) in a case of Dengue fever	4
Effect of extracorporeal cytokine removal on vascular barrier function in a septic shock patient	6
Combination of ECMO and cytokine adsorption therapy for severe sepsis with cardiogenic shock and ARDS due to Panton-Valentine leukocidin-positive Staphylococcus aureus pneumonia and H1N1	8
Cytokine Reduction in the Setting of an ARDS-Associated Inflammatory Response with Multiple Organ Failure	10
Observations in early vs. late use of CytoSorb haemadsorption therapy in critically ill patients	12
First case of toxic shock treated with haemadsorption by CytoSorb in the Netherlands	14
Case study of 8 patients with multiple organ failure treated additionally with CytoSorbents haemadsorption as adjunctive therapy in septic shock and severe SIRS in cardiac failure	16
Case report of 1 patient with multiorgan failure due to severe SIRS in cardiac failure treated additional with CytoSorbents haemadsorption as adjunctive therapy	18
CytoSorb, a novel therapeutic approach for patients with septic shock: A case report	20
First successful combination of ECMO with cytokine removal therapy in cardiogenic septic shock: A case report	22
Use of a novel hemoadsorption device for cytokine removal as adjuvant therapy in a patient with septic shock with multi-organ dysfunction: A case study	24
Septic shock secondary to β -hemolytic streptococcus-induced necrotizing fasciitis treated with a novel cytokine adsorption therapy	26
Effects of a novel cytokine haemadsorption system on inflammatory response in septic shock after cephalic pancreatectomy – A case report	28
Pattern of cytokine removal using an adsorption column CytoSorb during severe Candida albicans induced septic shock	30
Improvement of hemodynamic and inflammatory parameters by combined hemoadsorption and hemodiafiltration in septic shock: A case report	32
Hemoadsorption using CytoSorb beads (CytoSorbents) in a cirrhotic patient with septic multiorgan failure	34
Can cytokine adsorber treatment affect antibiotic concentrations? – A case report	36
Intermittent use of cytokine adsorption in combination with CRRT in a patient with necrotising pancreatitis, septic shock and MOF	38
Case series of patients with severe sepsis and septic shock treated with a new extracorporeal sorbent	39

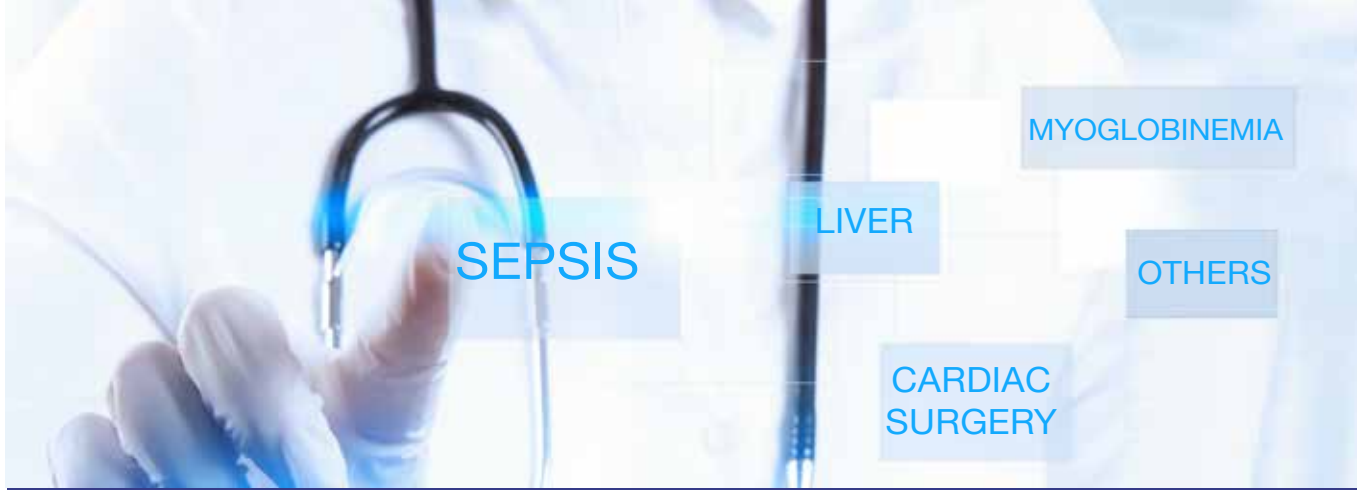

Table of contents

CARDIAC SURGERY

Treatment of post-cardiopulmonary bypass SIRS by hemoadsorption: a case series	40
Systemic Inflammatory Response Syndrome in Cardiac Surgery: New possibilities for treatment through the use of a cytokine adsorber during ECC?	44

LIVER

Application of Hemoadsorption in a Case of Liver Cirrhosis and Alcohol-Related Steatohepatitis with Preexisting Hepatitis C Infection	46
Hemoadsorption with Adult CytoSorb® in a Low Weight Pediatric Case – A Worldwide Premiere Procedure	48
First report of cytokine removal using CytoSorb in severe noninfectious inflammatory syndrome after liver transplantation	50
First description of SPAD combined with cytokine adsorption in fulminant liver failure and hemophagocytic syndrome due to generalized HSV-1 infection.	52
First use of CytoSorb with pruritus – A case report	54

MYOGLOBINEMIA

Hemoadsorption in Infection-Associated Rhabdomyolysis	56
CytoSorb in a patient with legionella-pneumonia associated rhabdomyolysis	58

A clinical experience of using extracorporeal cytokine adsorption device (CytoSorb) in a case of Dengue fever

Khan, Z.A.

Noble Hospital, Magarpatta Road, Hadapsar, Pune-411028, India.

J Evid Based Med Healthcare. 2016 3(87): 4779 - 4781.

Summary

This case study reports on a patient with Dengue fever, septic shock and multiple organ failure (MOF). Dengue is a mosquito-borne viral disease where it is thought that elevated cytokines (tumour necrosis factor alpha - TNF- α , interleukins and interferon gamma - IFN- γ) cause damage to the endothelial cells of the capillaries that results in fluid leakage. Here a 32 year old male patient was admitted to the intensive care unit and because of multiple organ failure, he was mechanically ventilated and put on renal replacement therapy. CytoSorb was used as an adjuvant supportive therapy on days 2, 4 and 6 of admission. The patient also received multiple transfusions to address thrombocytopenia and coagulopathy. The patient showed gradual improvement with a normalization of the central nervous system, improved oxygenation status, adequate renal function and normal platelet count (APACHE score 27 before and 12 at the end of CytoSorb treatment). Liver function also improved significantly. Serum Glutamic Oxaloacetic Transaminase – GOT (AST) fell from 15,690 U/L to 156 U/L, and Serum Glutamic Pyruvic Transaminase - GPT (ALT) fell from 3910 to 84 after CytoSorb treatment. The patient was discharged from ICU on day 13 and subsequently discharged. The authors note that CytoSorb seems to be a useful and safe extracorporeal therapy option to stabilize and help dengue shock patients with MODS to recover.

Case presentation

- 32 year old male patient who was transferred to a tertiary ICU with worsening multi organ failure, after presenting to a local hospital with fever, chills, dyspnea, yellow discoloration of skin and sclera the previous week
- On admission the patient was pyrexia (100°F, heart rate 120 – 130 bpm, respiratory rate 26 – 30 per min, leukocytosis 16400 μ L, with acute organ dysfunction (agitation, thrombocytopenia, hypoxia, kidney dysfunction, metabolic acidosis and arterial hypotension), sepsis and septic shock. His APACHE score on admission was 27
- Within 24 hours the patient needed to be mechanically ventilated because of worsening Acute Respiratory Distress Syndrome (ARDS) and hypoxia
- The patient received fluid optimization, nutritional support, antibiotics, proton pump inhibitors, treatments for hepatic encephalopathy, blood

products and other standard support therapy

Treatment

- CytoSorb was added as a supportive therapy due to the systemic inflammatory response and multiple organ dysfunction
- The patient received three sessions of six hours each on days 2, 4 and 6 of admission.
- No anticoagulation was used, blood flow rate was 250 mL/min

Measurements

- Clinical and laboratory parameters before and after CytoSorb treatment: Creatinine, hematocrit, leucocytes, platelets, mean arterial pressure (MAP), ARF - Acute Renal Failure, GCS - Glasgow Coma Scale, aPTT - Activated Partial Thromboplastin Time, GOT - Serum Glutamic Oxaloacetic Transaminase (AST), GPT - Serum Glutamic Pyruvic Transaminase (ALT)
- Arterial blood gas values before and after CytoSorb therapy: pH, PaCO₂ - Partial Pressure of Carbon Dioxide, PaO₂ - Partial Pressure of Oxygen, SBC - Standard Bicarbonate, (A-a) O₂ - Alveolar-arterial oxygen gradient mmHg, Base Excess

Results

- There were no major complications during or after the CytoSorb therapy except mild irritability that settled with sedatives
- Patient showed gradual improvement with APACHE score after the third cycle decreasing from 27 to 12
- As a result of the treatment:
 - Creatinine decreased from 3.96 to 1.59 mg/dL
 - Leucocytes from 16,3000 to 13,000 μ L
 - Platelets from 50,000 to 311,000 μ L
 - GCS from 9 to >10
 - Mean arterial pressure from 84 to 104 mmHg
 - GOT (AST) from 15690 to 156 U/L, GPT (ALT) from 3910 to 84 U/L
 - Serum lactate from 6.7 to 1.9 mmol/L

Clinical and laboratory examination of the patient before and after the treatment

Parameters	Before CytoSorb treatment	After CytoSorb treatment
APACHE score	27	12
Chronic organ dysfunction	No	No
ARF	Yes	No
Temp (°F)	100	99.8
Resp rate (bpm)	26-28	20-26
Sodium (mEq/L)	138	135
Potassium (mEq/L)	3.9	3.6
Creatinine (mg/dL)	3.96	1.59
Hematocrit	27.7%	26.7%
Leucocytes (per mcl)	16.3 x 10 ³	13.2 x 10 ³
Platelets (per mcl)	50,000	311,000
GCS	9	>10
Mean arterial pressure (mmHg)	84	104
aPTT (sec)	43	>60
GOT (U/L)	15,690	156
GPT (U/L)	3,019	84
Serum lactate (mmol/L)	6.7	1.9

ARF - Acute Renal Failure, GCS - Glasgow Coma Scale, aPTT - Activated Partial Thromboplastin Time, GOT - Serum Glutamic Oxaloacetic Transaminase, GPT - Serum Glutamic Pyruvic Transaminase.

Arterial blood gases value before and after CytoSorb therapy

Parameters	Before	After
pH	7.2	7.4
PaCO ₂ (mmHg)	28	34
PaO ₂ (mmHg)	37	215
SBC (mmol/L)	15	22.9
(A-a) O ₂ gradient (mmHg)	281.6	98
Base excess	-13	-1

PaCO₂ - Partial Pressure of Carbon Dioxide, PaO₂ - Partial Pressure of Oxygen, SBC - Standard Bicarbonate, (A-a) O₂ - Alveolar-arterial oxygen

Post-treatment period and follow-up

- Patient was transferred from ICU on day 13, and subsequently discharged fully ambulant

CONCLUSIONS

- CytoSorb helped to stabilize and revive this patient with dengue, MODS and shock
- The majority of laboratory parameters were within the normal range after the therapy and no major adverse events were reported during or after the CytoSorb therapy
- This is the first report of the clinical application of CytoSorb hemoadsorption in a case of dengue fever with MODS treated successfully with standard of care along with CytoSorb
- CytoSorb seems to be an interesting and safe option to stabilize and help dengue patients with MODS to recover

Effect of extracorporeal cytokine removal on vascular barrier function in a septic shock patient

David S¹, Thamm K¹, Schmidt BM¹, Falk CS², Kielstein JT¹.

¹ Department of Medicine, Division of Nephrology & Hypertension, Hannover Medical School, Hannover, Germany.

² Institute of Transplant Immunology, IFB-Tx, Hannover Medical School, Hannover, Germany.

J Intensive Care. 2017 Jan 21;5:12.

Summary

A 32-year-old female presented with septic shock and accompanying acute kidney injury to ICU. In spite of a broad anti-infective regimen, adequate fluid resuscitation, and high doses of catecholamines, she remained in refractory hypotensive shock. The extraordinary severity of septic shock suggested an immense overwhelming host response assumingly accompanied by a notable cytokine storm. Thus, a CytoSorb adsorber was added to the dialysis circuit. To analyze the endothelial phenotype in vitro before and after extracorporeal cytokine removal, the authors tested the patient's serum on human umbilical vein endothelial cells (HUVECs) and the effect on the endothelial integrity was assessed. The authors found severe alterations in cell-cell contacts, the cytoskeletal architecture, and profound functional permeability changes (in other words clinical vascular leakage syndrome) when blood from the patient taken prior to the CytoSorb adsorber was added to the HUVECs. However, the endothelial barrier was protected from these profound adverse effects when blood serum was collected after the CytoSorb adsorber (cytokine removal) and added to the HUVECs. In conclusion the benefit of extracorporeal cytokine removal with CytoSorb in septic shock patients might-at least in part-be promoted via protection of vascular barrier function.

Case presentation

- 32-year-old female patient with a 4-day history of fever, malaise, and cough was found unconscious and hypoxic by the emergency team
- The patient was successfully resuscitated and after initial treatment at a local hospital transferred to the authors institution for extracorporeal membrane oxygenation (ECMO) due to influenza pneumonia, which caused respiratory failure and severe ARDS
- She also had an abscess of her left breast that grew *Escherichia coli* bacteria
- Due to sepsis (peak CRP 222 mg/L; peak procalcitonin 81.2 µg/L) and accompanying acute kidney injury (AKI), the patient required additional organ support by continuous veno-venous hemodialysis (CVVHD)
- Sequential Organ Failure Assessment (SOFA) score was 18

- The patient remained in refractory hypotension despite a broad anti-infective regimen, adequate fluid resuscitation, and high doses of inotropes and catecholamines
- The severity of septic shock suggested an immense overwhelming host response assumingly accompanied by a notable cytokine storm such as that known from patients with toxic shock syndrome
- Therefore, a CytoSorb adsorber was additionally installed into the CVVH circuit

Treatment

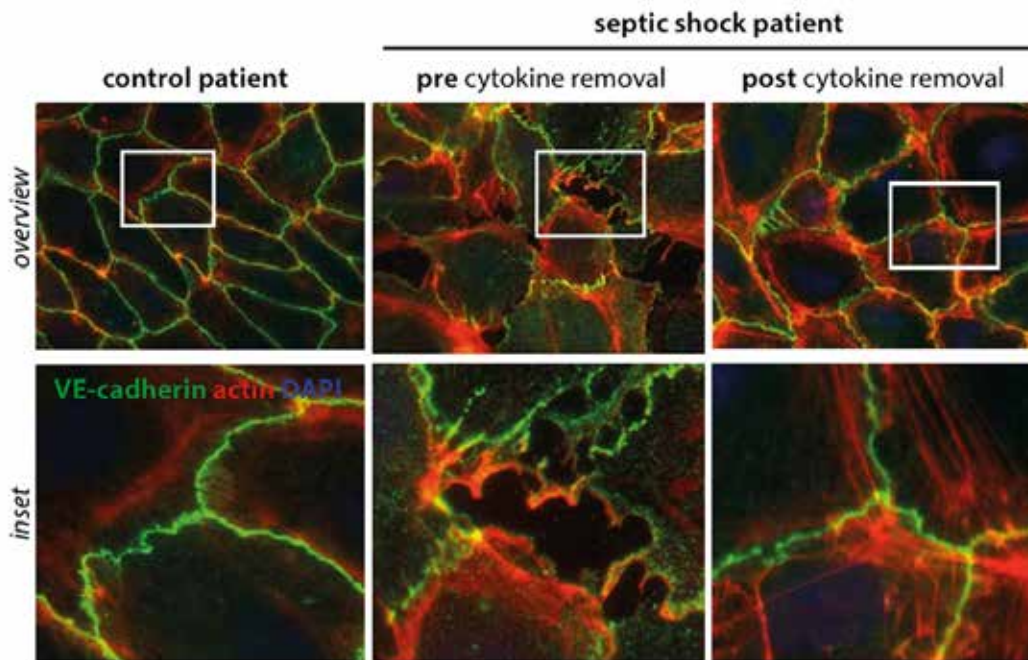
- One treatment with CytoSorb for a total of 24 hours
- CytoSorb was used in conjunction with CRRT performed in CVVHD mode

Measurements

- Demand for catecholamines and hemodynamics
- Cytokine, chemokine, and growth factor concentrations in serum (IL-1a, IL-6, IL-8, IL-9, IL-10, IL-13, FGF, GM-CSF, CXCL10 (IP-10), CCL2 (MCP-1), CCL4 (MIP-1b), PDGF-bb, RANTES, TNF-a, VEGF)
- Creatinine, lactate
- Removal of antibiotics
- Stimulation of endothelial cells with plasma from healthy control and the septic shock patient (pre- and post CytoSorb therapy)
- Transendothelial electrical resistance measurements to objectively quantify the functional permeability consequences of intercellular gaps

Results

- Improved hemodynamic stability within the process of cytokine removal - after 24 h of treatment, the mean arterial pressure (MAP) could be maintained above 65 mmHg with markedly reduced need for vasopressors, even allowing the removal of excessive fluids by ultrafiltration
- Noradrenaline doses could be reduced from 0.40 to 0.09 µg/kg/min after the 24 hour treatment (reduction to 0.11 µg/kg/min even within the first 12 hours)



Endothelial phenotype with respect to barrier function. Fluorescence immunocytochemistry staining for vascular endothelial (VE)-cadherin (green), F-actin (red), was performed on confluent human umbilical vein endothelial cells (HUVECs). Cells were treated for 30 min with media supplemented with 5% serum from an individual with septic shock before (2nd row) and after cytokine removal (3rd row); 5% healthy human serum served as a control (1st row). Scale bar 10 μ m

- During the course of the single treatment creatinine could be lowered from 242 to 70 μ mol/L and lactate from 3.1 to 0.9 mmol/L
- Significant removal of all cytokines and chemokines (except IL-13)
- Pre- and post-CytoSorb drug levels of antibiotics yielded a marked reduction for meropenem and piperacillin as well as a slight reduction for clindamycin
- Treatment of endothelial cells challenged with serum from the septic patient pre CytoSorb treatment exhibited structural alterations with an increase in permeability, the cellular correlate for the clinical “vascular leakage syndrome”, while cells stimulated with serum from the same patient after CytoSorb

treatment were comparable with cells from a healthy control (in other words, the integrity of cell junctions was better preserved after CytoSorb)

Patient follow-up

- Unfortunately, clinical and radiologic signs of severe hypoxic brain injury forced the authors to switch the therapeutic strategy to comfort care and the patient died the next day

CONCLUSIONS

- Extracorporeal cytokine removal using CytoSorb led to a stabilization of septic shock within hours
- Due to the observed removal of antibiotics, the authors recommend thorough therapeutic drug monitoring in septic patients, as with the use of any other extracorporeal removal strategies
- This is the first publication showing that a protective effect of CytoSorb on capillary integrity, and as a result, on microcirculation, can be assumed with a high probability
- There is no doubt that this report from a single patient is hypothesis generating in nature, so that a future systematic study is highly desirable

Combination of ECMO and cytokine adsorption therapy for severe sepsis with cardiogenic shock and ARDS due to Panton-Valentine leukocidin-positive *Staphylococcus aureus* pneumonia and H1N1

Lees NJ, Rosenberg A, Hurtado-Doce AI, Jones J, Marczin N, Zerriouh M, Weymann A, Sabashnikov A, Simon AR, Popov AF

Department of Anaesthetic and Critical Care, Harefield Hospital, Royal Brompton & Harefield NHS Foundation Trust, England

J Artif Organs 2016; 19(4): 399 – 402

Summary

Sepsis-induced cardiogenic shock in combination with severe acute respiratory failure represents a life-threatening combination that is often refractory to the conventional methods of treatment. Here the authors describe the case of a 33-year-old patient who developed acute cardiovascular collapse and ARDS secondary to superinfection of Panton-Valentine leukocidin-positive *Staphylococcus aureus* and H1N1 pneumonia who underwent successful combination therapy for severe sepsis-related cardiomyopathy and respiratory failure using extracorporeal membrane oxygenation and Cytosorb therapy. Use of the Cytosorb appeared to result in rapid resolution of neutropenia, reversal of toxic shock and rapid weaning off of the high dose vasopressor infusions.

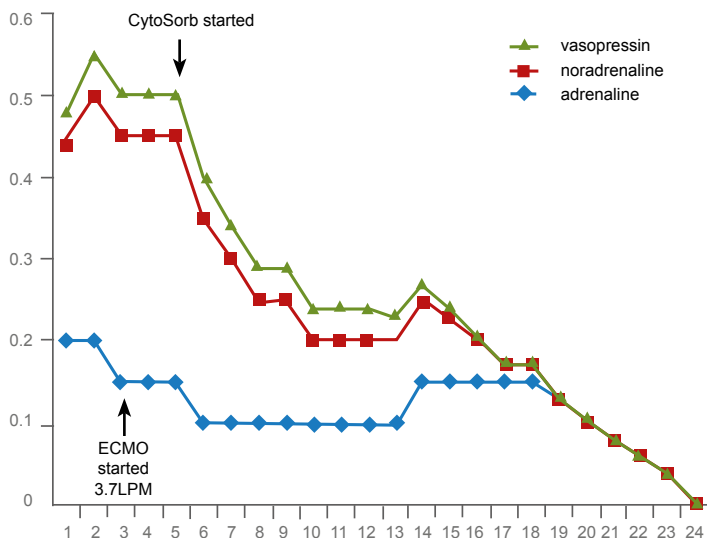
Case presentation

- 33-year-old previously fit female (5-month post-partum) presented to the local emergency department following a 4-day history of flu-like symptoms with breathlessness, delirium, chest, and abdominal pains
- On the initial assessment, she was pyrexial, tachypneic, tachycardic, and hypotensive with cool peripheries
- Examination and investigations revealed clinical evidence of severe acute respiratory failure with extensive air space shadowing throughout with hypoxemia and metabolic acidosis (pH 7.1, lactate 5 mmol/l, base deficit -11 mmol/l)
- Cardiac assessment by transthoracic echocardiography revealed severe left ventricular failure with a left ventricular ejection fraction (LVEF) of 5–15 %
- Furthermore, she was severely neutropenic (white blood cell count $0.6 \times 10^9/l$, neutrophils $0.3 \times 10^9/l$)
- She rapidly deteriorated requiring intubation and mechanical ventilation and treatment was initiated for community acquired pneumonia
- In addition, she required significant amounts of vasopressor and inotropic support to achieve an adequate mean arterial pressure, highlighting the central cardiovascular involvement in her critical state

- In view of clinical deterioration and cardiovascular and respiratory instability, she was transferred to the hospital of the authors for ongoing care and consideration of extracorporeal life support
- On arrival, she had severe respiratory failure with a Murray score of 3.7 (PaO_2 / FIO_2 ratio 11.1 kPa, PEEP 12, compliance 32 ml/cmH₂O, four-quadrant infiltration on chest radiograph)
- She was hypotensive with a MAP of 50 mmHg, despite high-dose infusions of norepinephrine (1–1.5 µg/kg/min) and vasopressin 0.04 U/h in addition to dobutamine 7.5 µg/kg/min
- Transthoracic echocardiography revealed a severely impaired, non-dilated left ventricle and normally functioning, non-dilated right ventricle
- There was metabolic acidosis (base deficit -6 mmol/l, lactate 4 mmol/l) and oliguria
- Care was initially supportive comprising mechanical ventilation, titration of high-dose inotropic and vasopressor agents, fluids, and continuous veno-venous hemodiafiltration
- She was treated empirically for severe sepsis and community acquired pneumonia and influenza. Subsequent analysis of sputum from direct bronchoscopy showed a heavy growth of *Staphylococcus aureus* (*S. aureus*) positive for expression of Panton-Valentine leukocidin (PVL). Viral PCR was also positive for H1N1 Influenza A. Clindamycin was added and intravenous immunoglobulin G (IVIg) therapy was commenced.
- In view of the severity of the combined respiratory and cardiac failure and evidence of worsening organ function, peripheral veno-arterial (VA) extracorporeal membrane oxygenation (ECMO) was instituted within 5 h of arrival and in view of the severe sepsis and high amount of vasopressors, CytoSorb was added to the hemofilter circuit

Treatment

- CytoSorb was added to the CVVH circuit (Prismaflex, Gambro, Sweden) and run parallel to the VA-ECMO circuit (Thoratec Centrimag pump at 4 L/min with inspired oxygen through the Medos hilitte 700LT oxygenator set at 100%)



Clinical course of the first 24 h, showing doses of inotropes and vasopressors after starting ECMO and CytoSorb therapies. Doses are in µg/kg/min (adrenaline and noradrenaline); units/h (vasopressin)

- Run time: One treatment session for 24 h
- Anticoagulation: Heparin, targeting activated partial thromboplastin time (aPPT) of 60–80 s
- Adsorber position: pre-hemofilter

Measurements

- Hemodynamics, inotropes and vasopressor doses
- Leukocytes and CRP levels
- Lactate

Results

- There was an improvement in oxygenation and gradual resolution of lactic acidosis after institution of the therapies
- Most notably, the initially very high doses of vasopressors could be weaned off after 12 h and she had no requirement for catecholamine support by 24 h
- The neutropenia also fully returned to normal by day 2 and the serum C-reactive protein level reduced
- There were no adverse events related to the treatment

Patient follow-up

- ECMO therapy was continued for a total of 9 days
- At the time of ECMO removal, lung compliance and oxygenation ($\text{PaO}_2/\text{FiO}_2$ ratio) had improved significantly; however, hypercapnia remained a problem. To facilitate removal of carbon dioxide and to allow ongoing protective mechanical ventilation, a less invasive mode of extracorporeal lung support was established using the Hemolung RAS (ALung Technologies, Pittsburgh, USA) remaining in place for 5 days without complication
- A percutaneous tracheotomy was performed on day 12
- Despite chest CT showing evidence of cavitating, necrotizing pneumonia, lung function continued to improve
- The tracheal cannula was removed on day 23 and the patient was discharged to the ward on day 30
- She was reviewed in the follow-up clinic 2 months later and was well, with normal heart function on echocardiography
- Her lung function was reduced (FEV1 60 %, FVC 56 %, TLCO 55 %), but she has remained asymptomatic

CONCLUSIONS

- This case is the first report of the successful use of extracorporeal support and CytoSorb hemoadsorption therapy in combination to treat a patient with severe acute respiratory failure, septic and cardiogenic shock due to PVL-S. aureus superinfection with H1N1
- The authors state, that the reversal of septic shock, the rapid weaning off of the high-dose vasopressor infusions as well as the quick resolution of neutropenia and reduction in CRP levels are unusual for such severe presentation, and that they feel that CytoSorb was a beneficial factor in the combination therapy with ECMO
- This case report also demonstrates that multiple extracorporeal technologies, including VA ECMO, hemofiltration, and hemoadsorption with CytoSorb can be successfully combined in severe septic shock with myocardial involvement

Cytokine Reduction in the Setting of an ARDS-Associated Inflammatory Response with Multiple Organ Failure

Traeger K, Schuetz C, Fischer G, Schroeder J, Skrabal C, Liebold A, Reinelt H
 Department of Cardiac Anesthesiology, University Hospital Ulm, Germany
Case Reports in Critical Care, Volume 2016 (2016)

Summary

This case study reports on a 45-year-old male who was admitted to the hospital with a small bowel obstruction due to torsion and immediately scheduled for surgical intervention. At anesthesia induction, the patient aspirated and subsequently developed a severe SIRS with ARDS and multiple organ failure requiring the use of ECMO, CRRT, antibiotics, and low dose steroids. Due to a rapid deterioration in clinical status and a concurrent surge in inflammatory biomarkers, CytoSorb was added to the CRRT blood circuit. The combined treatment resulted in a rapid and significant reduction in the levels of circulating inflammatory mediators. This decrease was paralleled by a marked clinical stabilization of the patient including a significant improvement in hemodynamic stability and a reduced need for norepinephrine and improved respiratory function and indirect measures of capillary leak syndrome. The patient could be discharged to a respiratory weaning unit where successful respiratory weaning could be achieved later on. The authors attribute the clinical improvement to the rapid control of the hyperinflammatory response and the reduction of inflammatory mediators using a combination of CytoSorb and the other therapies. CytoSorb treatment was safe and well tolerated, with no device-related adverse effects observed.

Case presentation

- 45-year-old male patient was admitted to hospital with small bowel obstruction due to torsion and immediately scheduled for surgical intervention
- At anesthesia induction the patient aspirated and immediately underwent bronchoscopy
- Laparotomy was performed and decompression of the small bowel was achieved
- During operation the patient developed severe respiratory failure with indication for installation of a veno-venous ECMO
- On ICU the patient developed severe ARDS, alveolar edema, systemic vasoplegia, marked capillary leakage, leucocytopenia and acute kidney injury grade 3 with indication for CRRT
- Further treatment included bronchoscopy, veno-arterial ECMO, protective ventilation, kinetic positioning and application of the sepsis bundle

- Due to a massive increase in markers of inflammation CytoSorb was added to the circuit
- During CytoSorb treatment, antibiotics were administered routinely as follows: meropenem 500 mg bolus followed by infusion of 1.45 mg/kg/h, anidulafungin prolonged infusion at 200 mg per day, and linezolid prolonged infusion 600 mg twice a day, with no dosage adjustment due to CytoSorb treatment reported

Treatment

- CytoSorb was used in conjunction with CVVHD added in pre-dialyzer position of the CRRT machine (Multifiltrate®, Fresenius Medical Care)
- Three treatments were consecutively performed for 85 hours in total (20h + 35h + 29h)
- Blood flow rate between 100-140 ml/min
- Regional anti-coagulation was achieved using a citrate-based protocol

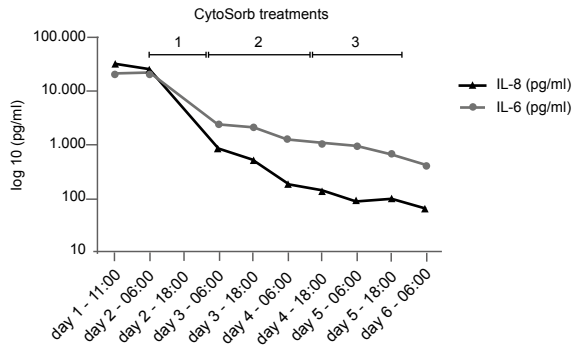
Measurements

- Course of IL-6 and IL-8 throughout the three treatments
- Need for norepinephrine throughout the treatment period
- Fluid balance during the three consecutive CytoSorb treatments

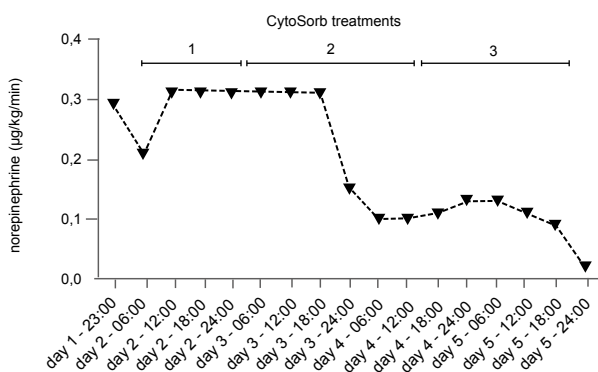
Results

- Pronounced decrease in the concentrations of IL-6 and IL-8 continuing to decrease further in the following days
- Clear hemodynamic stabilization and the need for norepinephrine was significantly reduced
- Respiratory function improved during the treatment course, with a disappearance of any signs of alveolar exudation
- Severity of capillary leakage (as demonstrated by daily fluid needs and daily fluid balance) became less apparent
- CytoSorb treatment was safe and well-tolerated with no device related adverse events, and easy to implement as part of the CVVH circuit

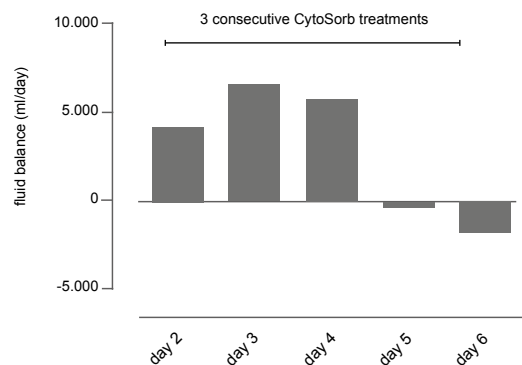
Course of IL-6 and IL-8 throughout the three treatments with the CytoSorb



Need for norepinephrine throughout the treatment period



Fluid balance during the three consecutive CytoSorb treatments



Patient follow-up

- At postoperative day 12, therapy was started with methylprednisolone, in order to inhibit fibroproliferation in the lung and risk of fibrosis during ARDS
- A percutaneous tracheostomy was performed on day 13
- By post-operative day 18, the patient's respiratory function, along with gas exchange and lung mechanics, on mechanical ventilation had sufficiently improved such that VA-ECMO was discontinued
- CRRT had to be continued for a period of 20 days and could then be stopped after sufficient recovery of renal function
- On day 27, the patient was transferred to a respiratory weaning unit where the patient was subsequently successfully weaned off mechanical ventilation.

CONCLUSIONS

- Stabilization and successful treatment of a complicated pulmonary aspiration post-surgical patient with septic shock and polymicrobial infection, severe exudative ARDS, renal failure, and a severe SIRS response with pronounced hypercytokinemia
- CytoSorb was easy to use and safe, and no device-related adverse events were observed
- Control over the patient's initial hyper-inflammatory response was a key element in helping to clinically stabilize the patient, allowing for organ recovery, and ultimately survival
- More randomized controlled studies using CytoSorb in critically-ill patients will help to establish the true benefit of the therapy

Observations in early vs. late use of CytoSorb haemadsorption therapy in critically ill patients

Kogelmann K, Druener M, Jarczak D
 Department of Anesthesiology, Hospital Emden, Germany
Critical Care 2016, 20(Suppl 2):P195

Summary

The aim of this case study conducted in 14 critically ill patients was to show the effectiveness of CytoSorb treatment used as adjunctive therapy. Increased survival occurred if treatment with the hemadsorption filter was started early (<48 h after diagnosis of septic shock) and patients who had a greater delay in start of therapy (>48 h after diagnosis of septic shock) had poor outcome. Start of CytoSorb therapy in nonsurvivors was by far later than in survivors. After CytoSorb therapy a pronounced decrease of catecholamine demand (norepinephrine $\mu\text{g}/\text{h}$ vs. thereby achieved MAP) was observed with catecholamine demand decreasing 10-fold. Blood lactate level was divided into halves. These observations implicate that a preferably early start of therapy not later than 24 hours after diagnosis of septic shock / severe SIRS is crucial for survival.

Background

- Several studies and in in-vitro data demonstrated that an additional treatment using CytoSorb may be helpful in patients with multiorgan failure due to increased cytokine levels
- CytoSorb is used as adjunctive therapy not only in septic multiorgan failure but also in severe pancreatitis and other critically ill patients
- The effect is based on biocompatible, highly porous polymer beads able to capture and adsorb cytokines and other middle molecules
- CytoSorb therapy has meanwhile been used in over 200 hospitals worldwide in more than 5,500 patients and is well tolerated and safe.

Methods

- Patients with severe SIRS and at least two organ failures due to acute infection were enrolled and assigned to receive an intervention with CytoSorb hemadsorption therapy
- One of the organ failures had to be acute kidney injury
- Exclusion criteria were: pregnancy or breast-feeding, age < 18 years, conditions of end-stage diseases

- Aim of this case study was to show the effectiveness of CytoSorb treatment used as adjunctive therapy in critically ill patients
- If after initial therapy following actual guidelines there was no decrease in catecholamine demand and kidney injury was persistent, CytoSorb therapy was initiated
- Data were collected before, during and after treatment and the demand of norepinephrine vs. the thereby achieved MAP was calculated ($\mu\text{g}/\text{h}$ vs. thereby achieved mmHg MAP)

Results

- Data from 14 patients were collected
- The focus of infection was abdominal (28.6 %), pneumonia (50 %) and pancreatitis (14.3 %)
- 42.8 % of patients were female, mean age was 56.4 years, overall survival was 35.7 % at a mean APACHE II Score of 37
- The authors observed a survival of 66.7 % when start of therapy was delayed less than 24 h
- Poor outcome increased in patients with late start of CytoSorb (survivors in delay < 48 h : 50 %, in delay > 48 h: none)
- Start of CytoSorb therapy in nonsurvivors was by far later than in survivors (61.3 h vs. 28.8 h)
- After CytoSorb therapy the authors observed a pronounced decrease of catecholamine demand (norepinephrine $\mu\text{g}/\text{h}$ vs. thereby achieved MAP): Catecholamine demand decreased 10-fold ($\mu\text{g}/\text{h}/\text{mmHg}$: 84.81 vs. 8.84)
- Blood lactate level was divided into halves (mg/dl: 42.7 vs. 20.2)

Fig. 1: μg Norepinephrine / mmHg MAP

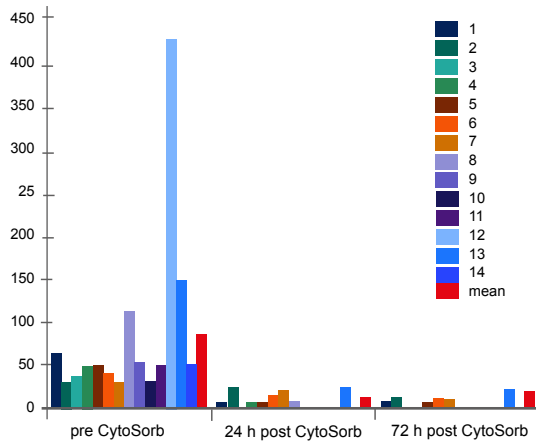


Fig. 2: Lactate (mg/dl) pre/post CytoSorb

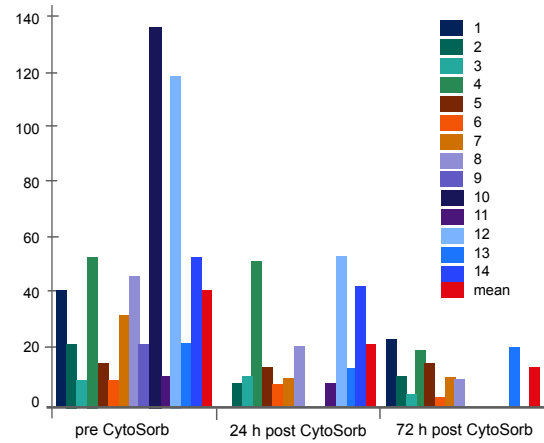


Fig. 3: Delay in start of therapy (h) & Patients characteristics

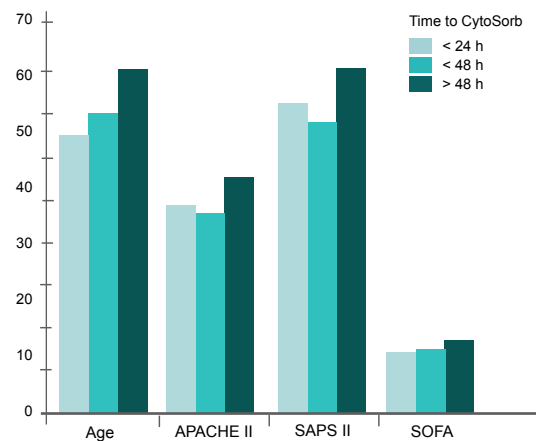
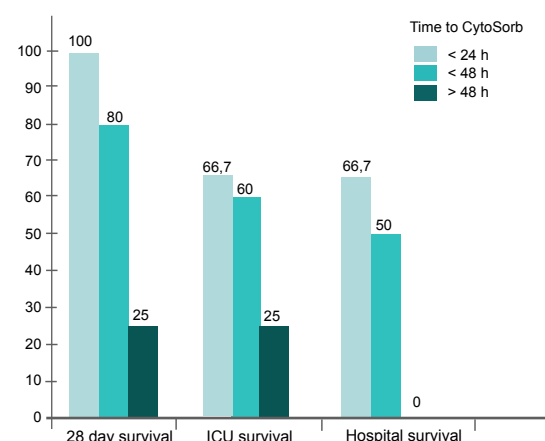


Fig. 4: Delay in start of therapy (h) / survival (%)



CONCLUSIONS

- The authors observed a pronounced reduction in catecholamine dosages and blood lactate values during CytoSorb therapy in these critically ill patients
- The patients in whom therapy was started early (<24 hours after diagnosis) showed a significantly higher survival rate than patients with a delay in the start of therapy
- These observations show that a preferably early start of CytoSorb therapy not later than 24 hours after diagnosis of severe sepsis / septic shock, could have a favorable effect on the probability of survival

First case of toxic shock treated with haemoadsorption by CytoSorb in the Netherlands

van der Linde GW, Grootendorst A

Department of Intensive Care Medicine, Maasstad Hospital, Rotterdam, The Netherlands

Neth J Crit Care. 24(2): 27-29

Summary

This case study reports on a 17-year-old male who reported to the pediatrician at a local rural hospital with complaints of pretibial pain in his right leg, after he accidentally cut his leg while in the fields a few days earlier. He was diagnosed for having a phlegmon with an abscess followed by surgical debridement with wound nettoyage with no clinical signs of subcutaneous emphysema or necrotizing fasciitis. Postoperatively the patient's condition deteriorated and after admission to ICU he developed erythema, spreading from the right lower leg to the right upper leg, abdominal wall and the left leg, consistent with toxic shock syndrome and subsequent development of septic shock due to invasive *S. aureus* infection with respiratory failure, hemodynamic instability treated with vasopressors, hydrocortisone and antibiotic therapy. Due to the disease severity, CRRT was initiated with a CytoSorb adsorber with the only goal to remove cytokines (despite absence of acute kidney injury and no need for renal replacement therapy). Within six hours after the start, the erythema progression stopped and after 12 hours the need for vasopressors diminished. The erythema diminished after a few hours and had disappeared after 24 hours. After cessation of CytoSorb physicians concluded that the patient was no longer septic and diuretics were started because of fluid overload. Respiration improved, the ventilator support was decreased and the patient was extubated on day 5 after admission, within 72 hours of cessation of CRRT. In the authors opinion, the patient would have survived without the CytoSorb, but they feel that his stay in our ICU might have been shortened by the adsorber treatment.

Case presentation

- 17-year-old male reported to the pediatrician at a local rural hospital with complaints of pretibial pain in his right leg, after he accidentally cut his leg while in the fields a few days earlier
- Diagnosis of a phlegmon with an abscess followed by surgical debridement with wound nettoyage with no clinical signs of subcutaneous emphysema or necrotizing fasciitis
- Postoperatively the patient's condition deteriorated and after admission to ICU he developed erythema, spreading from the right lower leg to the right upper leg, abdominal wall and the left leg, consistent with toxic shock syndrome
- Development of septic shock due to invasive *S. aureus* infection with respiratory failure, hemodynamic instability treated with vasopressors, hydrocortisone, antibiotic therapy
- Due to the disease severity, CRRT was initiated with a CytoSorb adsorber with the only goal to remove cytokines (despite absence of acute kidney injury and no need for renal replacement therapy)
- Antibiotic therapy consisting of clindamycin and ceftriaxone was initiated, adjustment of ceftriaxone dosage to 2 grams twice daily

Treatment

- CytoSorb was used in conjunction with CRRT (Baxter HF 19 Aquamax)
- One treatment was performed for 24 hours in total
- Blood flow rate between 240 ml/min
- Regional anticoagulation was achieved using a citrate-based protocol

Measurements

- Need for norepinephrine throughout the treatment period
- CRP, hemoglobin, Hct, MCV (fl), thrombocytes, leucocytes, INR, aPTT, urea, creatinine, phosphate, bilirubin, gamma GT, alkaline phosphatase, ALAT, ASAT, LDH, creatine kinase, albumin, lactate, pCO₂, pO₂, HCO₃⁻, base excess, saturation, SvO₂, PaO₂:FiO₂ ratio

Results

- Within six hours after the start, the erythema progression stopped and after 12 hours the need for vasopressors diminished
- After 24 hours, vital signs were: sinus tachycardia (112 beats/min), blood pressure 117/49 mmHg without vasopressors, no more fever
- The erythema diminished after a few hours and had disappeared after 24 hours

Patient follow-up

- After cessation of CytoSorb physicians concluded that the patient was no longer septic and diuretics were started because of fluid overload
- Respiration improved, the ventilator support was diminished and the patient was extubated on day 5 after admission, within 72 hours of cessation of CRRT
- On day 6, patient was transferred back to the local hospital for further revalidation

Lab values on admission and 24 hours after cessation of CytoSorb

Lab value	at admission	24 h after CytoSorb
C-reactive protein (mg/l)	316	156
Hemoglobin (mmol/l)	7.5	6.0
Hematocrit	0.33	0.29
MCV (fl)	86	92
Thrombocytes (10 ⁹ /l)	94	107
Leucocytes (10 ⁹ /l)	9.1	12.1
INR	1.2	1.1
aPTT (sec)	29	27
Urea (mmol/l)	5.2	
Creatinine (μmol/l)	83	81
Phosphate (mmol/l)	0.31	0.94
Magnesium (mmol/l)	0.93	0.96
Total bilirubin (μmol/l)	32	12
Direct bilirubin (μmol/l)	20	
Gamma GT (U/l)	63	75
Alkaline phosphatase (U/l)	74	
ALAT (U/l)	64	80
ASAT (U/l)	151	
LDH (U/l)	383	
Creatine kinase (U/l)	4,185	1,574
Albumin (mmol/l)	22	23
Lactate (mg/dl)	2.3	2.4
pH	7.47	
pCO ₂ (mmHg)	31	
pO ₂ (mmHg)	93 (6 liters O ₂)	
HCO ₃ ⁻ (mmol/l)	23	
Base excess	-1	
Saturation	98 %	
ScO ₂	70 %	
PaO ₂ :FiO ₂ ratio	233	

CONCLUSIONS

- This is the first publication on the use of CytoSorb in a patient with fulminant Toxic Shock Syndrome
- The hemodynamic stabilization and reduction of erythema after starting CytoSorb were impressive. The vasopressor dosages could be reduced massively as early as 6 hours after initiation of treatment
- The authors assume that the patient's stay on ICU was shortened considerably by the treatment
- Although the clinical value still has to be established, the first experiences with the CytoSorb adsorber are promising and justify further investigation

Case study of 8 patients with multiple organ failure treated additionally with CytoSorbents haemadsorption as adjunctive therapy in septic shock and severe SIRS in cardiac failure

Kogelmann K, Drüner M, Jarczak D
 Department of Anesthesiology, Hospital Emden, Germany
Infection. 2015 Aug;43 Suppl 1:1-73. Abstract No. 58

Summary

In this case series the authors aimed to investigate the effectiveness of CytoSorb treatment in 8 patients with sepsis/SIRS and multiple organ failure. They found a pronounced decrease in catecholamine demand and a distinct tendency in decrease of blood lactate levels during the treatment period and within 72 hours after CytoSorb therapy. However, no significant changes for SOFA-Score nor SAPS II-Score were detected. Importantly, compared with overall survival of about 45 % in severe sepsis including septic shock the authors could find a survival of 62.5 % in these patients. Treatment with CytoSorb was safe and without any noticed side effects.

Patients, pre-treatment and indication for CytoSorb treatment

- Seven patients with septic multiple organ failure and one patient with severe SIRS and MOF in cardiac failure treated additionally with CytoSorb as adjunctive therapy in septic shock
- The infectious focus was abdominal (four patients) and pneumonic (three patients), one patient was without any infection
- Initial therapy of these patients followed the Surviving Sepsis guidelines and focused on adequate volume therapy, differentiated catecholamine therapy (administering norepinephrine to achieve a mean arterial pressure of 60 mmHg), administering antibiotics not later than 1 hour after detection of septic shock and lung-protective ventilation
- If there was no decline of catecholamine demand even after an additional corticoid treatment for 24 hours, CytoSorb therapy was initiated
- Indication for haemadsorption therapy further included: at least two-organ failure with APACHE-2 Score higher than 25, no decline in requirement of norepinephrine despite adequate conventional therapy over a 24 hours period as well as the need for renal replacement therapy

Treatment

- Duration of therapy with CytoSorb was predefined to be between 24 and 72 hours
- Adsorber was changed every 24 hours

Measurements

- Patient characteristics: sex, age
- APACHE-2 score, ventilator days, length of stay (ICU and in-hospital) and survival
- Before, during and after CytoSorb treatment
 - SAPS II-score, SOFA-score, MAP, requirement of norepinephrine, blood lactate level
- Demand of norepinephrine ($\mu\text{g}/\text{h}$ vs. mmHg MAP) during therapy

Results

- Five patients were treated over a 72-h period, three patients for 48 h
- Only marginal differences in SAPS II and SOFA-score:
 - SAPS II-score at start 51.1 ± 11.74 , at the end: 38.6 ± 9.7
 - SOFA-score at start 11.1 ± 2.85 ; at the end 9.75 ± 2.2
- Slightly decreased blood lactate [mg/dl]
 - At start 29.2 ± 17.2 , at the end: 13.9 ± 7.3
- Huge impact on need for catecholamines with respect to the demand of norepinephrine [$\mu\text{g}/\text{h}$] vs. the thereby achieved MAP [mmHg]
 - At start: 52.7 ± 26.9 ; at the end: 3.6 ± 4.7 [$\mu\text{g}/\text{h} * \text{mmHg}$]
- Compared with overall expected survival of about 45 % in severe sepsis including septic shock the authors could find a survival of 62.5 % in these patients

Table 1: Descriptives (MAP=mean arterial pressure, NOR=norepinephrine, LOS=length of stay)

	Minimum	Maximum	Mean	SD
Age (years)	36	80	58.12	14.96
SAPS II-score	36	73	51.12	11.74
SOFA-score	8	46	11.12	2.85
MAP (mmHg)	35	70	59.62	10.87
NOR ($\mu\text{g/h}$)	2,000	4,000	2,910	720
Lactate (mg/dl)	9.2	53.1	29.20	17.21
Ventilator (days)	16	50	31.12	11.48
LOS ICU (days)	18	71	39	15.62
LOS hospital (days)	43	88	51.17	17.06
APACHE-2 score	27	52	35.62	9.99

Table 2: Data at the beginning (Start= 1) and after treatment (End = 2) with CytoSorb (MAP=mean arterial pressure, NOR=norepinephrine)

	Minimum	Maximum	Mean	SD
MAP (1) (mmHg)	35	70	59.62	10.87
MAP (2) (mmHg)	65	85	77.5	7.07
NOR (1) ($\mu\text{g/h}$)	2,000	4,000	2,910	720
NOR (2) ($\mu\text{g/h}$)	0	1,000	280	390
SOFA-score (1)	8	16	11.12	2.85
SOFA-score (2)	7	14	9.75	2/18
SAPS II-score (1)	36	73	51.12	11.74
SAPS II-score (2)	25	55	38.62	9.73
Lactate (1) (mg/dl)	9.2	53.1	29.2	17.21
Lactate (2) (mg/dl)	4.7	23.9	13.97	7.31
NOR μ /MAP (1) ($\mu\text{g/h} * \text{mmHg}$)	33.25	114.28	52.76	26.96
NOR μ /MAP (2) ($\mu\text{g/h} * \text{mmHg}$)	0	12.50	3.62	4.75

Fig. 1 μg Norepinephrine/mmHg MAP

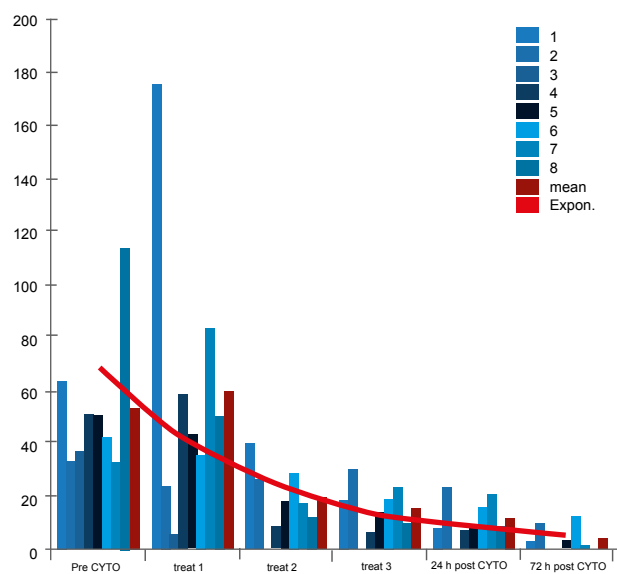
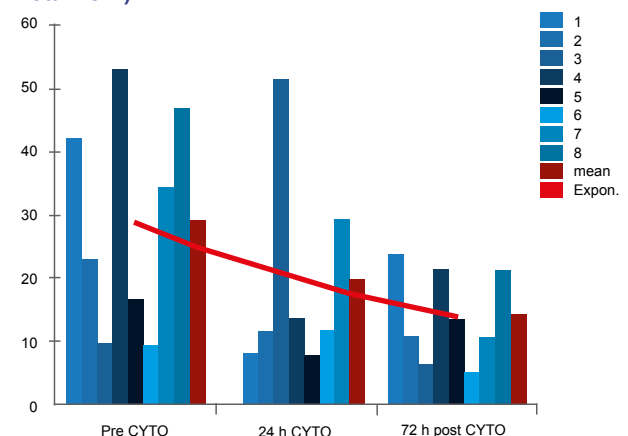


Fig. 2 Blood lactate level (mg/dl pre/post CytoSorb treatment)



CONCLUSIONS

- Indication for CytoSorb therapy in this case series is comparable to former indication for activated recombinant human Protein C (drotrecogin alfa activated): at least 2 organ failures with APACHE-2 score higher than 25, no decline in requirement of norepinephrine despite adequate conventional therapy over a 24 hours period
- Treatment with CytoSorb in these 8 patients was safe and without any noticed side effects
- The major effect seen was a pronounced decrease in catecholamine demand
- Compared with overall expected survival of about 45 % in severe sepsis including septic shock the authors could find a survival of 62.5 % in these patients
- Whether other patients could profit from this adjunctive treatment is still uncertain and should be investigated

Case report of 1 patient with multiorgan failure due to severe SIRS in cardiac failure treated additional with CytoSorbents haemadsorption as adjunctive therapy

Kogelmann K, Drüner M, Jarczak D
 Department of Anesthesiology, Hospital Emden, Germany
Infection. 2015 Aug;43 Suppl 1:1-73. Abstract No. 126

Summary

This case study reports on a patient with severe SIRS and multiple organ failure in cardiogenic shock due to refractory cardiac arrhythmia, diffuse hypokinesia and an ejection fraction of ~45 % with a heart rate of 36 bpm. After 24 hours of conventional treatment, CytoSorb therapy and CRRT was initiated due to high and stable catecholamine support associated with a persistent renal failure. During CytoSorb therapy the authors found a decrease in catecholamine demand of more than 95 % and 72 hours after therapy the patient had been free of catecholamines. SOFA score did not change while SAPS II-score decreased to 50 % of its initial value. Blood lactate, creatinine and liver enzymes decreased markedly and normalized after 2 weeks. Treatment using CytoSorb adsorption in this patient had shown great effect, been safe and was without any noticed side effects. The authors note that CytoSorb therapy was helpful even in a patient with severe cardiac failure and thereby initiated severe SIRS.

Case presentation

- Patient was admitted to the hospital after she collapsed several times at home
- Patients medical history included peripheral arterial obstructive disease, arterial hypertension and former minor stroke
- Glasgow Coma scale was 11, heartrate was 20 bpm, hypothermia was measured with 30 °C, metabolic acidosis with pH 7.2, no blood pressure measurable
- After immediate resuscitation the patient developed severe SIRS and multiple organ failure in cardiogenic shock due to refractory cardiac arrhythmia
- Initial ultrasound of the heart function showed diffuse hypokinesia and an ejection fraction (EF) of about 45 % at a heartrate of 36 bpm
- 24 hours of conventional treatment (differentiated catecholamine therapy with combined norepinephrine and adrenaline, ultrasound guided volume therapy, lung-protective ventilation, administering temporary cardiac pacemaker)

- Ultrasound control showed diffuse dysfunction and hypokinesia with an EF of 50 %
- Laboratory tests and electrocardiography at admission showed neither myocardial infarction nor infectious problems but highly elevated liver enzymes and creatinine (Table 1)
- Due to high and stable catecholamine support associated with a persistent renal failure, CytoSorb therapy and CRRT was initiated

Treatment

- Duration of therapy with CytoSorb was 72 hours
- Adsorber was changed every 24 hours

Measurements

- Before, during and after treatment
 - SAPS II-score, SOFA-score
 - Mean arterial pressure
 - Requirement for norepinephrine
 - Blood lactate level
- During therapy
 - Demand of norepinephrine ($\mu\text{g/h}$ vs. mmHg MAP)

Results

- During CytoSorb therapy the authors found a decrease in catecholamine demand of more than 95 % and 72 h after therapy the patient had been free of catecholamines
- SOFA score did not change; SAPS II-score decreased to 50 % of its initial value (Table 1, Fig. 2)
- Blood lactate decreased from 46.9 to 21.4 mg/dl (Table 1, Fig. 2)
- GOT decreased from 5,355 U/L to 431 U/L 3 days later; GPT decreased from 4,858 U/L to 888 U/L and LDH decreased from 6,859 to 242 U/L (Table 1)

Table 1: Descriptives, scores, laboratory values

	Pre Cyto	Cyto day1	Cyto day 2	Cyto day 3	24 h post Cyto	12 days post Cyto
SAPS II-score	73	68	52	53	41	25
SOFA-score	16	18	14	18	17	4
MAP (mmHg)	35	50	70	65	75	70
μ NOR vs MAP ($\mu\text{g}/\text{h} \cdot \text{mmHg}$)	114.2	50	11.4	9.2	6.7	0
Lactate (mg/dl)	55	50	46.9	43.4	29.9	10
Creatinine (mg/dl)	2.48	3.2	1.84	1.36	1.29	1.8
CK (U/L)	227	1,694			577	41
LDH (U/L)	3,140	6,859			242	264
GOT (U/L)	2,698	5,355			431	27
GPT (U/L)	2,195	4,858			888	38
Leuko (1000/ μ l)	15.2	10.1	4.74	5.36	11.2	10.3
PLT (1000/ μ l)	157	99	68	44	36	250
PCT (ng/ml)					0.67	0.47

Fig. 1 μg Norepinephrine/h * mmHg MAP

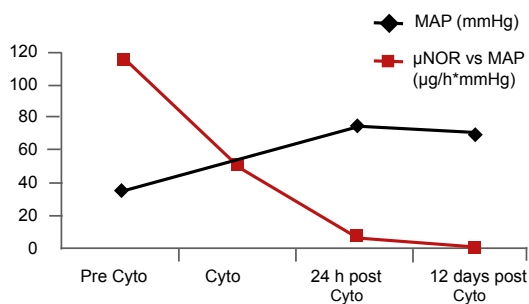
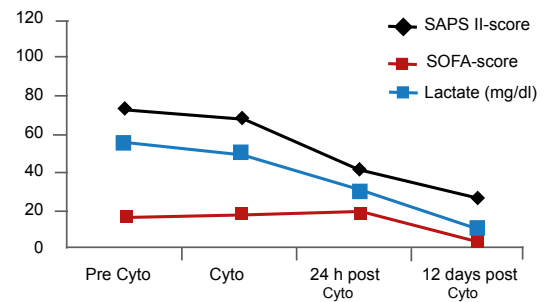


Fig. 2 SAPS II-score, SOFA-score, Lactate (mg/dl)



Patient follow-up

- 12 days after treatment the liver enzymes were back at normal values
- Chest X-ray 10 days after admission showed only slight effusions, 6 days later ventilation could be finished and the patient was alert, vigilant and in stable clinical condition without any catecholamine demand
- During therapy, blood natriuretic peptide level was determined tenfold increased with 1,959 pg/ml as a marker of left ventricular dysfunction
- In coronary angiography there was a three vessel coronary artery disease with ischemic cardiomyopathy as a reason for the patients cardiac arrhythmia which led to the severe SIRS

CONCLUSIONS

- Treatment using CytoSorb adsorption in this patient with severe cardiac failure due to ischaemic cardiomyopathy was associated with great clinical improvement, was safe and without any noticed side effects
- The authors note that CytoSorb therapy was helpful even in a patient with severe cardiac failure and thereby initiated severe SIRS

CytoSorb, a novel therapeutic approach for patients with septic shock: A case report

Hinz B, Jauch O, Noky T, Friesecke S, Abel P, Kaiser R
 Department of Anesthesiology and Intensive Care, Hospital Guestrow, Germany
Int J Artif Organs. 2015 Sep 18;38(8):461-4.

Summary

This case study reports on a 72-year-old male patient with periodically recurring infectious episodes who was admitted with the suspicion of urosepsis. In the following hours his hemodynamic situation deteriorated markedly, exhibiting respiratory-metabolic acidosis, elevated inflammatory marker plasma levels, a severely disturbed coagulation, increased retention parameters, liver dysfunction, and confirmation of bacteria and leucocytes in urine. After admission to the ICU in a state of septic shock the patient received renal support with additional hemoadsorption using CytoSorb. Three CytoSorb sessions were run during the following days. The first and consecutive second session resulted in a reduction of procalcitonin, C-reactive protein and bilirubin and a markedly reduced need for vasopressors while hemodynamics improved significantly (i.e. cardiac index, extravascular lung water). Due to a recurring inflammatory "second hit" episode, another session with CytoSorb was run, resulting in a marked decrease in leukocytosis and liver (dys)function parameters. The rapid hemodynamic stabilization with reduction of vasopressor needs within hours and reduction of the capillary leakage as well as a quick reduction in infection markers were the main conclusions drawn from the use of CytoSorb in this patient. Additionally, treatment appeared to be safe and was well tolerated.

Case presentation

- 72-year-old male patient was admitted with suspicion of urosepsis
- Condition: progressing hemodynamic instability, elevated inflammatory marker plasma levels, severely disturbed coagulation, increased retention parameters, liver dysfunction, as well as a proof of bacteria and leucocytes in the patients' urine
- Upon take over to ICU, patient was in septic shock with increasing need for fluids + vasopressors
- Due to a further increase of retention parameters and decreasing spontaneous diuresis the patient received continuous renal replacement therapy
- Ultrafiltration was performed to counteract massive volume overload and an increase of extravascular lung water

- As inflammatory markers remained high, the decision was made to additionally install a CytoSorb hemoadsorption column into the CVVHD circuit

Treatment

- Three CytoSorb sessions were run during the following days (1st session 24 hours, an immediately following 2nd session for 6 hours, 3rd session was 5 days later for 24 hours due to a recurring inflammatory second hit episode with increasing infection markers)
- Blood flow rate was kept at 180 ml/min and anticoagulation was achieved using heparin targeting a partial thromboplastin time (PTT) of 60 – 80 seconds controlled every 8 hours
- The CytoSorb adsorber was placed in a pre-dialyzer position

Measurements

- Laboratory: leucocytes, platelets, PCT, CRP, urea, creatinine, ALT, AST, bilirubin
- Clinical: cardiac index, extravascular lung water index, noradrenaline dose, mean arterial pressure, fluid balance, urine output

Results

- Drop of PCT, C-reactive protein and bilirubin
- MAP stabilized and the need for norepinephrine could be reduced from 0.8 down to 0.13 µg/kg*min and was tapered out 48 hours after termination of the second treatment
- Dobutamine infusion (10 mg/h) could be stopped straight after the second treatment
- Hemodynamics improved significantly with a cardiac index increasing from 3.22 before the first to 4.5 l/min/m² after the second treatment while extravascular lung water improved from 18.5 to 7.8 ml/kg in the course of the two treatments

CVVH was started on day 3. CytoSorb treatments (consecutive treatments 1 and 2) were performed on days 5 and 6, as shown in the table

Markers of inflammation and organ dysfunction throughout the treatment period:

	reference	Day 1	Day 2	Day 3	Day 4	Day 5	Day 6	Day 7	Day 8
Leucocytes (x10 ⁹ /µl)	4.6 - 10.2	12.6	16.7	18.2	16.5	17.7	18.8	20.5	20.4
Platelets (x10 ⁹ /µl)	150 - 400	72	57	43	41	28	47	56	85
Procalcitonin (µg/l)	0 - 0.5	N/A	>200	>200	46.87	N/A	26.37	19.25	11.61
C-reactive protein (mg/l)	0 - 5	92.7	157.1	245.6	203.2	N/A	133.4	90.9	74.9
Urea (mmol/l)	5.3 - 8.9	13.5	17.2	10.4	6	N/A	5.7	5.5	5.8
Creatinine (µmol/l)	71 - 106	297	324	225	156	N/A	158	150	143
ALT (µmol/l*s)	0 - 0.85	3.15	7.37	4.21	1.79	N/A	1.68	1.56	1.52
AST (µmol/l*s)	0 - 0.85	3.43	7.53	3.15	1.34	N/A	1.46	1.41	1.21
Bilirubin (µmol/l)	0 - 19	42.5	61.3	98.4	112.6	N/A	100.6	76.4	59

Mean arterial pressure, vasopressor dose and fluid balance over time:

	Day 1	Day 2	Day 3	Day 4	Day 5	Day 6	Day 7	Day 8
Peak noradrenaline dose (µg/kg/min)	0.8	0.7	0.19	0.3	0.29	0.15	0.12	0.02
Corresponding MAP (mmHg)	57	75	85	75	76	77	85	77
Fluid balance (ml/day)	+9,026	+7,645	+1,459	+19	+1,070	+980	+57	+2,559
Total fluid supply (ml/day)	10,050	8,250	6,400	3,850	4,350	4,300	4,150	5,065
Urine output (ml/day)	229	805	561	61	122	0	96	307
Average ultrafiltration rate (ml/hour)	-	-	250	160	100	150	175	100
Ultrafiltrate withdrawal (ml/day)	-	-	4,380	3,870	2,350	3,320	4,000	2,200

- Albumin levels measured before and during both CytoSorb treatments did not change
- No adaptation of antibiotic dosage (daptomycin, clarithromycin and ceftazidim) at any time

Patient follow-up

- 3rd CytoSorb session resulted in a marked decrease of leukocytosis, CRP, and liver dysfunction parameters (ALT, AST, bilirubin)
- After regaining clinical stability the patient was transferred to the University Hospital of Greifswald (Germany) due to more advanced diagnostic testing methods for the yet not accomplished

- focus search and because of their experience in the use of CytoSorb hemoadsorption, in case the patient should develop further complications
- Diagnostic testing revealed a spondylodiscitis and the focus was surgically eradicated
- Probably due to the long previous antimicrobial therapy, no underlying germ could be detected
- During the next days, organ functions and inflammatory status improved further, accompanied by a considerable improvement of the patients' general condition
- After discharge, the patient showed no further infectious episodes in the follow-up period

CONCLUSIONS

- In this patient CytoSorb therapy appeared to contribute to regain control over the patients' inflammatory response
- Treatment appeared to be safe and was well tolerated
- Main effects of CytoSorb: rapid hemodynamic stabilization with reduction of vasopressor needs within hours and reduction of the capillary leakage as well as a quick reduction of infection markers
- Further studies are necessary to elucidate to what extent these favorable consequences are attributable to the adsorber itself

First successful combination of ECMO with cytokine removal therapy in cardiogenic septic shock: A case report

Bruenger F, Kizner L, Weile J, Morshuis M, Gummert JF
 Clinic for Thoracic and Cardiovascular Surgery, Heart and Diabetes Center (HDZ) North
 Rhine-Westphalia, Bad Oeynhausen, Germany
Int J Artif Organs. 2015 Feb 3;0(0):0

Summary

This case study reports on a 39-year-old patient presenting at a hospital with fulminant ARDS and cardiogenic septic shock. After implantation of a veno-arterial ECMO for circulatory support the patient developed acute renal failure making initiation of CVVH necessary. Due to a complete cardiac arrest in both ventricles, a left ventricular assist device (LVAD) in combination with right ECMO (rECMO) was implanted despite manifest septic conditions. In the post-operative course his condition deteriorated drastically and a CytoSorb hemoadsorption device was therefore installed in the CVVH circuit resulting in a decrease of IL-6, procalcitonin, and C-reactive protein concomitant with significantly reduced vasopressor support. No adverse device-related side effects were documented during or after the treatment sessions. This is the first clinical case report of a highly septic patient treated with the combined use of LVAD, rECMO, CVVH, and CytoSorb. The combination was practical, technically feasible, and beneficial for the patient and might represent a reasonable approach to improve survival in patients with multiple organ dysfunction necessitating several organ supportive techniques.

Case presentation

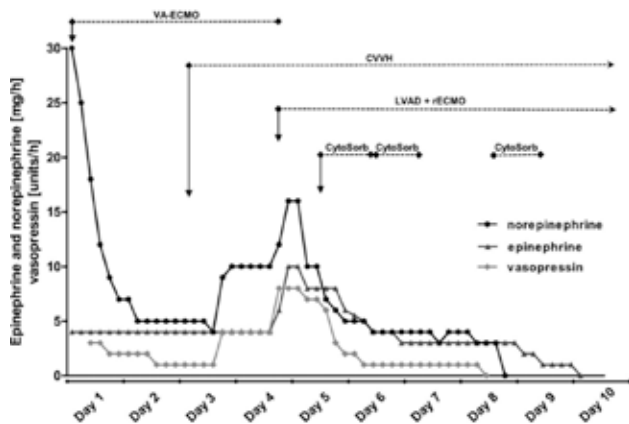
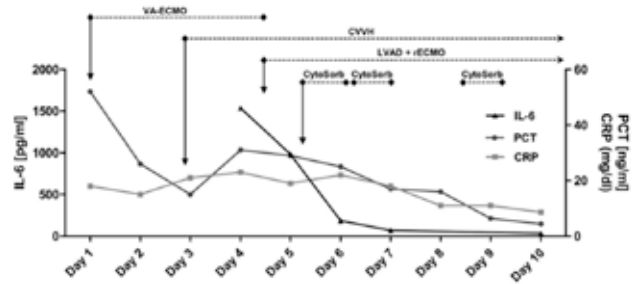
- A 39 year old male with a history of dilated idiopathic cardiomyopathy (LV-EF 20 %) was scheduled for regular ambulatory check up in the hospital from 2006 to 2012
- Medical history included secondary pulmonary hypertension, mitral valve insufficiency grade II - III, chronic renal failure, hypothyroidism and nicotine- and anabolic abuse
- A dual-chamber implantable cardioverter-defibrillator (ICD) was implanted already in 2006 and the patient was planned for heart transplant as from January 2007
- In early January 2013 the patient had been at the HDZ Bad Oeynhausen for a 3-day routine check and presented one week later at an external hospital with complaints of dyspnea

- After a short period of primary non-invasive ventilation the patient drastically deteriorated, was intubated and further ventilated mechanically
- Subsequent chest X-ray confirmed massive bilateral infiltrates
- Within several hours the patient developed a fulminant ARDS and cardiogenic septic shock
- Implantation of a veno-arterial ECMO on site and transport back to HDZ
- Patient developed an acute renal failure on top of his chronic renal insufficiency making CVVH necessary while the need for vasopressors increased drastically
- Due to a global cardiac akinesia and high risk of intracardial thrombosis, decision was made for implantation of a left ventricular assist device (LVAD) in combination with a right ECMO (rECMO) in exchange for the va-ECMO
- Operation was carried out despite full-blown sepsis with poor post-operative clinical condition
- As last resort decision, a CytoSorb hemoadsorption device was installed into the CVVH circuit

Treatment

- CytoSorb was installed into the CVVH circuit (AK200®; Gambro)
- Sessions were run on the first day as well as on day 2 and 4 after the operation over periods of 18 to 21 h each
- Blood flow rates were between 155 ml/min and 240 ml/min
- Anticoagulation was achieved using heparin, targeting a partial thromboplastin time (PTT) of 60 to 80, monitored every 4 h

Treatment regimen and course of IL-6, procalcitonin, and C-reactive protein before, during, and after treatment with CytoSorb



Treatment regimen and need for vaso-pressors before, during and after treatment with CytoSorb

Measurements

- Inflammatory markers (IL-6, CRP, PCT) as well as need for vasoactive substances (norepinephrine, epinephrine, vasopressin) were determined

Results

- With start of the CytoSorb therapy in combination with ECMO, inflammatory markers IL-6, procalcitonin, and CRP markedly decreased during treatment and continued to decrease further in the following days
- Also vasopressors could be reduced significantly and were stopped during (for norepinephrine and vasopressin) and shortly after (for epinephrine) the last treatment

- No negative effects on platelet count were observed
- During the entire treatment period (4 days in total) the patient received Linezolid, Meropenem, Moxifloxacin, Voriconazol and Acyclovir as boluses with no adaptation of dose at any time

Patient follow-up

- The rECMO was explanted 19 days and ventilation stopped 27 days after the treatment
- For regeneration of the kidney the patient received CVVH for another 21 days and could be discharged from ICU 38 days and from the hospital 76 days after the last CytoSorb session with the LVAD Heartware system
- The patient is still listed for transplantation

CONCLUSIONS

- This is the first clinical case report in a patient treated with LVAD, rECMO, CVVH, and CytoSorb in a combined fashion
- The combination was practical, technically feasible and highly beneficial for the patient
- After commencement of CytoSorb treatment, the patient's inflammatory status improved and vasopressor support could be reduced and tapered out
- No adverse or any device-related side effects were documented during or after the treatment
- Taken together, CytoSorb could be simply used in combination with ECMO, resulting in considerable benefits for the patient, thus representing a reasonable approach to improve survival in patients with several organ dysfunctions and the need for multiple organ supportive techniques

Use of a novel hemoadsorption device for cytokine removal as adjuvant therapy in a patient with septic shock with multi-organ dysfunction: A case study

Basu R, Pathak S, Goyal J, Chaudhry R, Goel RB, Barwal A
 Department of Critical Care and Artemis Health Institute, Gurgaon, Haryana, India
Indian J Crit Care Med 2014;18:822-4

Summary

This case study reports on a 36-year-old female diagnosed to have septic shock (urosepsis) with multi-organ dysfunction (ARDS, AKI, arterial hypotension) and a low perfusion state. SOFA score was 15, MODS score 10 and APACHE II score 30. CytoSorb was added along with CRRT and three consecutive treatments were run in the following three days. After initiation of therapy the patient improved hemodynamically. During the further course urine output increased with improvement in ventilator parameters. SOFA score at the end of treatment was 4, MODS score was 5 and APACHE II score was 7. No adverse events occurred and laboratory parameters before and after CytoSorb therapy were within a normal range. This case report suggests that CytoSorb therapy in septic shock patients with multi-organ failure might be an option as rescue therapy.

Case presentation

- 36-year-old female was admitted to hospital with complaints of general body ache for the last 3 days, malaise and breathing difficulty for the last 2 days before admission
- The patient had a history of diabetes mellitus type II, obstructive sleep apnea, hypertension, hypothyroidism and morbid obesity
- On examination, patient had tachycardia, tachypnea and leukocytosis
- Patient was suspected to have an urinary tract infection
- Immediate initiation of antibiotics, fluid resuscitation and mechanical ventilation
- Patient continued to deteriorate with decreasing urine output
- SOFA score was 15, MODS score 10 and APACHE II score 30
- Diagnosis of septic shock (urosepsis) and MODS (ARDS, AKI, arterial hypotension) with initiation of renal replacement therapy (CVVH) in combination with CytoSorb

Treatment

- Patient received 3 consecutive CVVH sessions with CytoSorb in the following 3 days
- Flow rate was maintained at 250 ml/min
- Patient was anticoagulated with heparin to a target aPTT of 30–40 s

Measurements

- Need for vasopressors
- Hemoglobin, Hematocrit, Leucocytes, Platelets, aPTT, INR, Lactate, Total protein, FBS/RBS
- Sodium, Potassium, Calcium
- Creatinine, Urea
- SGPT, SGOT

Results

- Quick improvement of hemodynamics during CytoSorb therapy
- SOFA, MODS and APACHE II scores decreased significantly
- Antibiotic therapy was conducted with Meropenem 3 x 500 mg p.d., without dosing adaptation during CytoSorb therapy

Vasopressor schedule before and after CytoSorb therapy

Vasopressor	Dose before CytoSorb therapy	Dose after CytoSorb therapy		
		Day 1	Day 2	Day 3
Epinephrine (µg/kg/min)	0.6	0.6	Nil	Nil
Norepinephrine (µg/kg/min)	0.1	1.0	0.2	0.02
Dopamine (µg/kg/min)	20	20	5	Nil
Vasopressin (IU/min)	0.06	0.06	0.02	Nil

Laboratory parameters before and after treatment with CytoSorb

Parameter	Before treatment	After treatment	Parameter	Before treatment	After treatment
Hemoglobin (g/dL)	9.9	8.1	Urea (mg/dL)	19.1	21.2
Hematocrit (%)	31.9	25.7	Sodium (mmol/L)	128.5	139.9
Leucocytes (mm ³)	52.1	9.6	Potassium (mmol/L)	4.5	3.9
Platelets (mm ³)	359	100	Calcium (mmol/L)	1.00	1.11
aPTT (s)	29.3	32.3	Total protein (g/dL)	8.4	5.5
INR	1.24	1.2	FBS/RBS (mg/dL)	96	145
Lactate (mmol/L)	4.4	0.7	SGPT (U/L)	849	420.1
Creatinine (mg/dL)	2.33	1.58	SGOT (U/L)	769.6	269.1

aPTT: Activated partial thromboplastin time; INR; International normalized ratio; FBS/RBS: Fasting blood sugar/Random blood sugar; SGPT: Serum glutamic pyruvic transaminase; SGOT: Serum glutamic oxaloacetic transaminase

CONCLUSIONS

- This study reports on a successful outcome in a case of septic shock and MOF where CytoSorb was used as an adjuvant therapy
- CytoSorb in combination with CVVH helped to quickly stabilize hemodynamics
- With a high predicted mortality (~70-80 %) the treatment managed to reduce SOFA score, MODS score and APACHE II score significantly
- Therapy was well tolerated with no adverse effects
- CytoSorb therapy in septic shock patients with MOF might be an option as rescue therapy

Septic shock secondary to β -hemolytic streptococcus-induced necrotizing fasciitis treated with a novel cytokine adsorption therapy

Hetz H, Berger R, Recknagel P, Steltzer H.

Department of Anesthesiology and Intensive Care Medicine, AUVA Meidling Emergency Hospital, Vienna, Austria
Int J Artif Organs. 2014 May;37(5):422-6

Summary

This case study reports on a 60-year-old female who was admitted to hospital due to a forearm fracture. After surgical wound care by osteosynthesis the patient developed surgical wound infection progressing to necrotizing fasciitis with additional proven infection from β -hemolytic streptococcus. The patient went into septic shock exhibiting a full picture of a MODS. Therefore, the patient was treated with CytoSorb therapy over a period of four days, resulting in a significant reduction of IL-6 and an overall improvement of the patient's condition. In this case, CytoSorb seems to be an interesting and safe extracorporeal therapy to stabilize and bridge septic patients to surgery or recovery.

Case presentation

- 60-year-old female with no pre-existing diseases except hypertension and hypothyroidism
- Initial indication: radius fracture of the right forearm after an accident
- Immediate wound care by application of a plaster splint
- Operative osteosynthesis on the same day
- Swelling of the forearm expanding to the upper arm
- Collapse of the patient
- Transfer to ICU with septic shock
- Initiation of antibiotics and fluid therapy
- Requirement for vasopressors
- Development of oliguric acute renal failure and ARDS
- Initiation of CVVH and mechanical ventilation
- APACHE II score of 19 and a SOFA of 8
- Proven infection with β -hemolytic streptococci

Treatment

- Initiation of three CytoSorb hemoperfusion sessions on the first day as well as on day 3 and 4 after ICU admission in combination with standard continuous hemodialysis-CVVHD
- Treatment time: 36 hours in the first and 17-18 hours in the two following procedures
- Blood flow rates: 100 ml/min
- Dialysate flow: 2,000-2,150 ml/h
- Anticoagulation: regional citrate within the external blood circuit

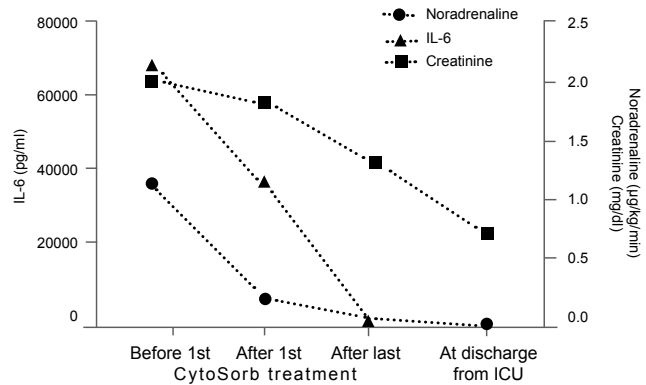
Measurements

- Leucocytes, platelets
- Need for vasopressors
- IL-6
- Creatinine, cumulative urine output

Results

- CytoSorb effectively and significantly reduced IL-6 levels
- After the first session, IL-6 plasma concentration decreased from 70,000 to 39,100 pg/ml (-44.3 %). The final IL-6 level after the third session was 66 pg/ml
- CytoSorb treatment was paralleled by a significant decrease of vasopressor need
- Antibiotic therapy was conducted with Ampicillin and Fosfomycin, with no reported adaption of dosage during CytoSorb therapy
- The patient could be successfully stabilized until surgical control of the infectious source was achieved

Plasma concentrations of IL-6 and creatinine and the need of noradrenaline during the course of the three treatment sessions until discharge from the ICU



Markers of inflammation, organ dysfunction, and need for vasopressors

	Before first Cyto-Sorb treatment	After first Cyto-Sorb treatment	After last Cyto-Sorb treatment	At discharge from ICU
Leucocytes ($\times 10^3 \mu\text{l}$)	1,850	13,810	29,000	6,760
Platelets ($\times 10^3 \mu\text{l}$)	19,4000	74,000	49,000	244,000
IL-6 (pg/ml)	70,000	39,100	66	14.5
Cumulative urine output (ml/day)	200	410	410	2,500
Creatinine (mg/dl)	2.07	1.88	1.37	0.79
Need for noradrenaline ($\mu\text{g}/\text{kg}/\text{min}$)	1.18	0.24	0.08	0

Post-treatment period and follow-up

- After the third CytoSorb treatment, hemofiltration was continued without CytoSorb as the need for vasopressors was significantly decreased and IL-6 levels were back in a normal range
- Despite considerable reduction of IL-6 levels, enucleation (amputation) was inevitable
- The general condition improved and the patient could be extubated 4 days after the third CytoSorb treatment

CONCLUSIONS

- Treatment was safe and well-tolerated, without adverse events
- CytoSorb significantly reduced IL-6, a predictor of mortality in sepsis and surrogate for cytokine storm
- The patient could be successfully stabilized until surgical infectious source control was performed
- CytoSorb in combination with CVVHD and regional citrate anticoagulation could be run continuously for up to 36 hours
- Hemoadsorption using CytoSorb seems to represent a promising approach for an effective and safe treatment of severe sepsis and septic shock

Effects of a novel cytokine haemoadsorption system on inflammatory response in septic shock after cephalic pancreatectomy – A case report

Tomescu D, Dima SO, Tănăsescu S, Tănase CP, Năstase A, Popescu M
 Department of Anesthesiology and Critical Care III, Fundeni Clinical Institute, Bucharest, Romania
Romanian Journal of Anaesthesia and Intensive Care 2014;21(2):134-138

Summary

This case study reports on a 50-year-old man with postoperative septic shock after undergoing cephalic pancreatectomy for a pancreatic cystic tumor. In total, two consecutive CVVH sessions with CytoSorb were performed over a period of 64 hours. The clinical effects associated with CytoSorb resulted in a rebalancing of cytokine levels and translated into a more stable hemodynamic profile with a stable cardiac output and normalization of systemic vascular resistance index and decreased vasopressor requirements. The technology was simple to use and could be easily added to conventional CVVH machines. The therapy was well tolerated with no adverse effects. The timing of CytoSorb use, whether early (after onset of SIRS) or late (after onset of organ dysfunction), has still to be established.

Case presentation

- 50 year old man was admitted to the ICU on the 5th postoperative day with hypotension, neurologic dysfunction and lactic acidosis after undergoing cephalic pancreatectomy for a pancreatic cystic tumor
- Laboratory test results showed an elevated white blood count (WBC) 13,560 / μ l, C-reactive protein (CRP) of 75.5 mg/l, procalcitonin (PCT) 0.529 ng/ml, elevated bilirubin level of 7.6 mg/dl and lactic acidosis (pH = 7.12, base excess – 8 mmol/L and lactate 3.5 mmol/l)
- Treatment was initiated with fluid resuscitation and broad spectrum antibiotics
- The clinical state gradually improved over the next four days except for the neurologic deficit
- On day 5 of ICU stay an acute inflammatory response was noted
- Deterioration of neurologic status and development of ARDS
- Microbiological examination of the peritoneal fluid sample showed infection with *Candida albicans* and *Klebsiella pneumoniae*

- Antibiotics and anti-fungal drugs were administered starting the same day
- Diagnosis of septic shock with initiation of renal replacement therapy in combination with CytoSorb

Treatment

- CytoSorb was applied in combination with standard CVVH on Prismaflex® (Gambro)
- Two consecutive CVVH sessions with CytoSorb over a period of 64 hours (24 hours each)
- Anticoagulation was achieved using heparin

Measurements

- Parameters were determined before and after each CytoSorb treatment
- Cytokines and chemokines, PCT, CRP, white blood count
- Hemodynamic parameters (SVRI, cardiac output)

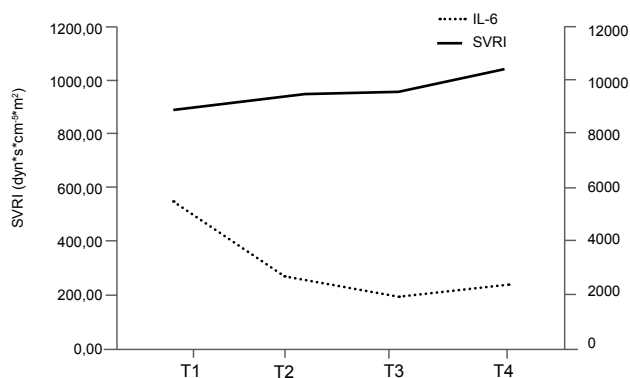
Results

- Improvement in hemodynamics comparing parameters before the 1st and after the 2nd session:
 - stable cardiac output (4.7 l/min/m²)
 - increase in systemic vascular resistance index from 890 to 1,040 dyn*s*cm⁻⁵*m²
 - decrease in vasopressor dose from 4 to 0.4 mcg/kg/min
- Decrease of inflammatory markers comparing levels before the 1st and after the 2nd session:
 - CRP from 400 mg/l to 283 mg/l
 - PCT from 100 ng/ml to 46 ng/ml
 - WBC count decreased from 16,630 / μ l to 10,310/ μ l

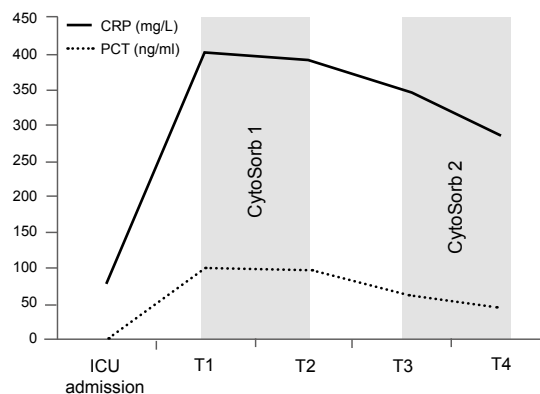
Cytokine values during the use of CytoSorb

	GM-CSF	IFN μ	IL-1 β	IL-2	IL-4	IL-5	IL-6	IL-7	IL-8	IL-10	IL-12p70	IL-13	MCP1	TNF α
Reference range	<5,38	<0,5	<2,62	<21,81	<13,91	<12,94	<7,25	<26,54	<20,2	<14,23	<12,79	<18,07	<281,61	<16,09
T1	21.14	17.05	14.00	25.62	21.25	2.02	5,440.67	53.08	897.17	89.89	13.69	21.54	10,112.48	155.45
T2	16.63	15.16	8.73	22.11	13.23	<2.00	2,653.45	51.31	857.52	112.21	13.68	18.84	5,589.22	102.53
T3	32.65	27.45	7.79	25.78	20.68	<2.00	1,965.46	51.31	279.04	311.02	12.96	18.45	14,966.42	265.49
T4	14.49	14.48	6.62	23.07	12.66	<2.00	2,294.89	50.86	347.16	350.05	13.69	18.45	4,884.68	252.59

T1 before first CytoSorb treatment, T2 after the first CytoSorb treatment
T3 before the second CytoSorb treatment, T4 after second CytoSorb treatment



The use of CytoSorb was associated with a more stable haemodynamic profile with near normal values for systemic vascular resistance



Dynamics of sepsis markers C-reactive protein (CRP) and procalcitonin (PCT)

- Rebalance in cytokine levels comparing levels before and after each session:
 - decrease in pro-inflammatory cytokines especially IL-1 β and TNF α
 - increase of anti-inflammatory cytokine levels, especially IL-10 and IL-8
 - marked reduction in (IFN γ)
 - reduction in WBC correlated with a marked decrease in both MCP-1 and GM-CSF
- Antiinfective therapy was conducted with Meropenem, Fluconazole and Colistin, with no reported adaption in dosage during CytoSorb therapy

Post-treatment period and follow-up

- Decision to control the septic source was made, but the patient died 24 hours after the second CytoSorb was dismantled due to cardiac arrhythmia (ventricular fibrillation) unresponsive to resuscitation manoeuvres

CONCLUSIONS

- The use of CytoSorb in combination with CVVH managed to re-establish a balance between pro- and anti-inflammatory cytokines that lead to a stable hemodynamic profile
- The technology was simple to use and could be added to conventional CVVH machines
- Therapy was well tolerated with no adverse effects

Pattern of cytokine removal using an adsorption column CytoSorb during severe *Candida albicans* induced septic shock

Bracht H, Schneider EM, Weiß M, Hohmann H, Georgieff M, Barth E
 Department of Anesthesiology, University Hospital Ulm, Germany
Infection (2013) 41 (Suppl 1):S1–S90; Abstract No. 133

Summary

This case study reports on a 46 old female with hypodynamic septic shock and documented candidemia infection. CRRT was started in combination with CytoSorb therapy. Within 24 hours of hemoadsorption, vasopressor and inotropic support could be withdrawn. Several inflammatory mediators (e.g. IL-6, 8, 10) could be reduced significantly. Interestingly, the authors also found an almost perfect immunological reconstitution of a variety of immune parameters including HLA-DR. This is the first successful use of CytoSorb during candida sepsis.

Case presentation

- A 46 old female was admitted to ICU with hypodynamic septic shock and documented candidemia after infection of an i.v. port
- On admission the patient was highly vasopressor and inotrope dependent and developed multiple organ failure
- Hemodynamic situation was desperate with accompanying low output syndrome

Treatment

- CRRT was started and additional hemoadsorption with CytoSorb was initiated for 24 hours

Measurements

- Levels of IL-1 β , IL-4, IL-8 as well as soluble CD25 (sCD25), lipopolysaccharide binding protein (LBP), Ferritin and tumor necrosis factor α (TNF α) were measured before and after hemoadsorption therapy
- Hemodynamic variables and vasopressor requirements were recorded at baseline and after 24 hours of hemoadsorption

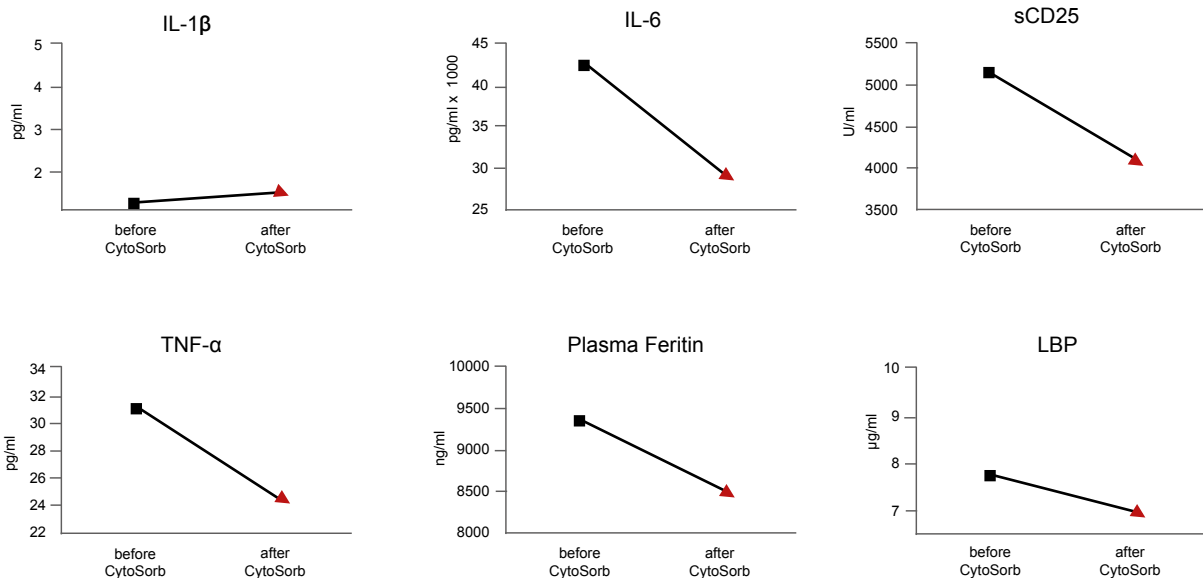
Results

- After 24 hours of hemoadsorption, norepinephrine requirements decreased dramatically from 0.7 to 0.2 $\mu\text{g}/\text{kg}/\text{min}$ and inotropic support with Levosimendan could be withdrawn
- The patient showed an improvement in hemodynamic parameters with a decreasing heartrate, stabilized MAP and improved cardiac output
- Serum lactate concentration decreased from 15 to 3.4 $\mu\text{mol}/\text{l}$.
- IL-1 β concentrations remained unchanged, but all other proinflammatory cytokines as well as the acute phase proteins TNF- α and Ferritin decreased dramatically
- Lipopolysaccharide binding protein (LBP) was not elevated before and after filtration
- Metabolic parameters improved by elevation in base excess
- Flow cytometric analysis revealed an almost perfect immunological reconstitution of a variety of immune parameters including HLA-DR

Hemodynamic, metabolic and gas exchange variables before and after hemoadsorption

	baseline	after hemoadsorption
Heartrate (bpm)	133	100
MAP (mmHg)	62	81
Cardiac Index (L/min/m ²)	1.9	2.9
Stroke volume variation (%)	14	7
Core Body Temperature (°C)	36.2	36.3
Base Excess (mmol/l)	-14.5	6.0
paO ₂ (mmHg)	125	128
paCO ₂ (mmHg)	27.1	38.2

Levels of IL-1 β , IL-6, sCD25, TNF- α , Plasma Ferritin and LBP before and after hemoadsorption.



CONCLUSIONS

- First successful demonstration of CytoSorb use during candida sepsis
- Whether the improvement in the hemodynamic situation was also influenced by simultaneously initiated inotropic support cannot be ruled out
- Accompanying gram-negative or -positive infection could also have contributed to the sustained effects
- Further studies need to elaborate indication criteria for hemoadsorption and the differences between bacterial- and fungal-induced severe sepsis and septic shock

Improvement of hemodynamic and inflammatory parameters by combined hemoadsorption and hemodiafiltration in septic shock: a case report

Mitzner SR, Gloger M, Henschel J, Koball S
 Department of Medicine, Division of Nephrology, University of Rostock, Rostock, Germany
Blood Purif. 2013;35(4):314-5.

Summary

This case study reports on an 80-year-old male diagnosed of having pneumogenic septic shock. The patient was in clinical need for renal replacement therapy and therefore started on citrate-anticoagulated CVVHD in combination with CytoSorb hemoperfusion for 24 hours.

In the further course, plasmatic IL-6 and other markers of inflammation as well as need for vasopressors could be reduced drastically while treatment was safe and well tolerated. This is the first clinical case report in a patient with acute-on-chronic kidney failure and septic shock.

Case presentation

- 80 year old male who was stable on chronic hemodialysis for more than 12 months
- Past history included coronary artery disease with a myocardial infarction 14 months ago, end-stage renal disease due to nephrosclerosis, arterial hypertension and diabetes mellitus type II
- Admission of patient to the emergency department after collapse at the end of a regular dialysis session
- On examination, patient had fever (39.2°C), moist bilateral rales, O₂-saturation 79 %, BP 126/60 mmHg, HR 130 bpm, lactic acidosis with pH 7.1, APACHE II 33, SAPS II 48
- Later blood cultures remained negative, however, bronchoalveolar lavage was positive for staphylococcus aureus
- Upon further deterioration of the circulatory situation, patient was diagnosed of having pneumogenic septic shock
- Need for mechanical ventilation and admission to ICU, start of noradrenaline 0.2 µg/kg/min
- Interleukin 6 level was elevated to 665 pg/ml

Treatment

- Initiation of one CytoSorb hemoperfusion session for 24 hours in combination with standard citrate-anticoagulated CVVHD

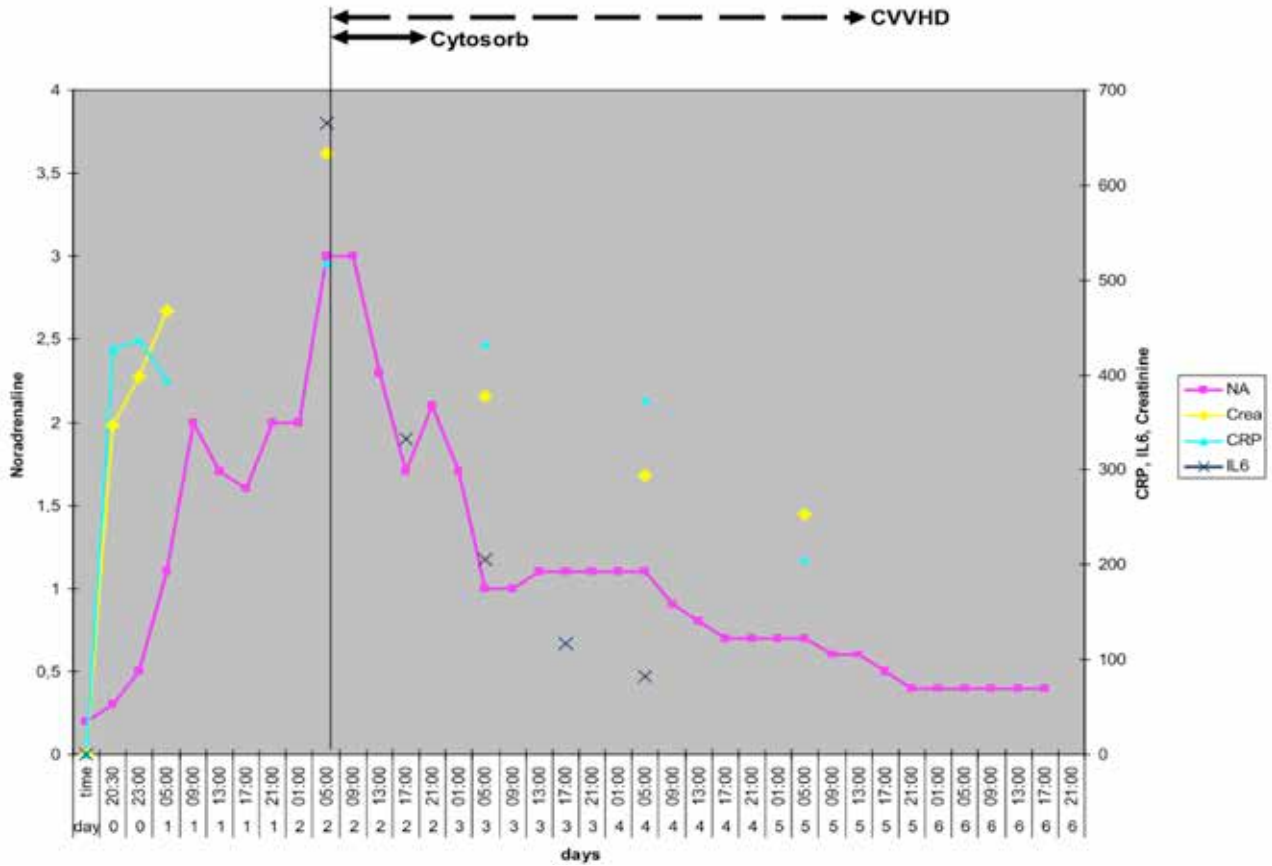
Measurements

- IL-6, CRP, creatinine, procalcitonin and leukocytes
- Need for noradrenaline

Results

- Noradrenaline could be reduced from a maximum of 3.0 to 0.4 µg/kg/min while MAP remained stable
- Values of IL-6, CRP, creatinine, procalcitonin, and leukocytes decreased during treatment and continued to decrease in the following days
- Antibiotic therapy was conducted with Ceftriaxone and Clarithromycine, with no reported adaption of dosage during CytoSorb treatment

Impact of combined hemoadsorption with CVVHD and the CytoSorb column on inflammatory and haemodynamic parameters. Time course of NA ($\mu\text{g}/\text{kg}/\text{min}$), creatinine (crea, $\mu\text{mol}/\text{l}$), CRP (mg/l), and IL-6 (pg/ml) from admission to the ICU until day 6



CONCLUSIONS

- First clinical case report in a patient with acute-on-chronic kidney failure and septic shock
- Hemoadsorption with CytoSorb in combination with CVVHD
- Treatment appeared safe and effective in this single treatment

Hemoadsorption using CytoSorb beads (CytoSorbents) in a cirrhotic patient with septic multiorgan failure

Gruber A, Firlinger F, Lenz K, Clodi M

Department of Internal and Intensive Care Medicine, Konventhospital Barmherzige Brueder, Linz, Austria
Infection (2013) 41 (Suppl 1):S1–S90; Abstract No. 056

Summary

In this case study a 37-year-old patient with alcoholic liver cirrhosis and septic shock with multiorgan failure due to bilateral pneumonia (staphylococcus aureus) was successfully treated with CytoSorb. The authors found an immediate improvement in organ function with stabilization of hemodynamics, as well as pulmonary and renal function. This is the first successful clinical case of a patient with sepsis and multi organ failure on the basis of alcoholic liver cirrhosis treated with standard of care plus CytoSorb.

Case presentation

- 37 year old patient with alcoholic liver cirrhosis
- Admission to ICU because of multiple organ failure due to bilateral pneumonia with staphylococcus aureus sepsis
- Despite antibiotic treatment, deterioration of the patient (cardiovascular instability, renal insufficiency, hepatic encephalopathy, and respiratory failure)
- Calculated CLIF SOFA Score of 18 and original SOFA score of 16 (estimated mortality > 90 %)
- Ventilation of the patient with pressure support
- Hemodynamic stabilization with noradrenaline, terlipressin and hydrocortisone
- Plasma IL-6 concentration 27,423 pg/ml
- Treatment of anuria with CVVHD

Treatment

- CytoSorb was applied in combination with standard CVVHD on Prismaflex® (Gambro)
- Three consecutive CytoSorb treatment sessions over a period of 54 hours
- Anticoagulation was achieved using citrate
- Blood flow of 140 ml/min

Measurements

- CRP, IL-6, PCT
- Bilirubin
- Need for vasopressors

Results

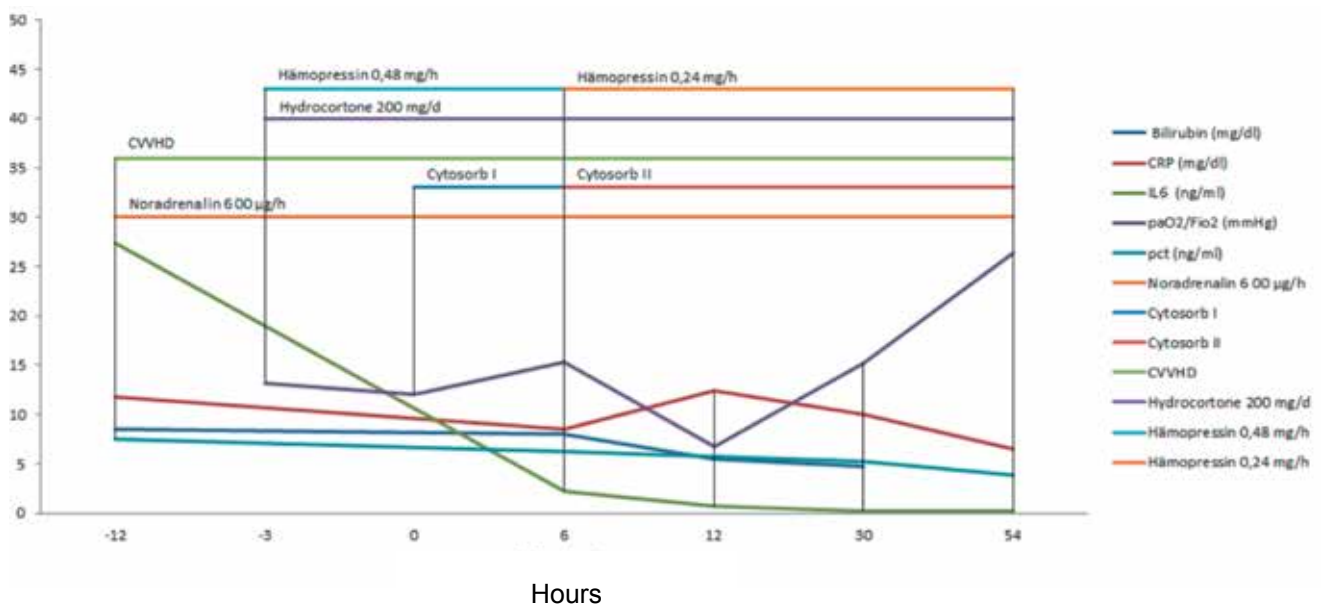
- IL-6 concentration dropped to 2266 pg/ml after the first, to 812 pg/ml after the second and to 151 pg/ml after the third CytoSorb treatment
- Patient improved hemodynamically within 6 hours after the first hemoperfusion and noradrenaline could be stopped after this time period
- Cardiac index increased from 4.3 l/m² to 6.6 L/m² but dropped again to 4.3 l/m² before starting the second CytoSorb treatment
- FiO₂ could be reduced to 0.55 and pressure support to 14 mmHg after the second CytoSorb treatment
- Urine output increased and CVVHD could be stopped after 3.5 days of CytoSorb treatment
- Levels of bilirubin, PCT and CRP could be reduced significantly during the three treatment sessions

Post-treatment period and follow-up

- The patient survived and is still alive 4 months after this event

Time course of Interleukin 6, C-reactive protein, Procalcitonin and Bilirubin with extracorporeal therapy and medical treatment

Treatment time in h	-12	-3	0	6	12	30	54
Bilirubin (mg/dl)		8.5			8	5.5	4.7
CRP (mg/dl)	11.8			8.5	12.4	10	6.5
IL-6 (pg/ml)	27,423			2,260	762	151	250
PCT (ng/ml)	7.52			6.22		5.24	3.9
PaO ₂ /FiO ₂ (mmHg)		13.2	12	15.3	6.7	15.2	26.4



CONCLUSIONS

- First successful clinical case of a patient with sepsis and multi organ failure on the basis of alcoholic liver cirrhosis treated with standard of care plus CytoSorb
- Treatment was well tolerated with no adverse events
- Interleukin 6 concentrations could be dramatically reduced and a hemodynamic stabilization occurred within hours after starting the therapy

Can cytokine adsorber treatment affect antibiotic concentrations? – A case report

Zoller M, Döbbeler G, Maier B, Vogeser M, Frey L, Zander J
 Department of Anesthesiology and Institute of Laboratory Medicine, University Hospital of Munich Großhadern, Germany
J Antimicrob Chemother 2015 Mar 18. pii: *dkv068*. (Epub ahead of print)

Summary

This case study reports on a male patient with septic shock and multiple organ failure who was admitted to the ICU. The patient's condition was characterized by an excessive inflammatory response. Initial laparotomy revealed an ischemic bowel with peritonitis with jejunum and colon segmental resection and ileotransverse colostomy being performed. Immediate antibiotic treatment with meropenem was started and linezolid was added 5 hours after admission. Due to persisting excessive cytokine storm, adjuvant therapy with a CytoSorb adsorber was initiated with a total of 4 treatments in the further course. Over the following days, the patient's condition substantially improved. The use of CytoSorb in this patient with severe septic shock proved to be effective (decay of IL-6) and safe (antibiotic levels well above the lower of therapeutic range). This is the first time an in vivo pharmacokinetic monitoring of Linezolid and Meropenem during treatment with CytoSorb is described. In case therapeutic drug monitoring is not available, high loading doses or shorter intervals between antibiotic administrations could be used to achieve adequate antibiotic levels.

Case presentation

- Male patient with septic shock and multiple organ failure was admitted to ICU at the University Hospital of Munich
- Initial laparotomy showed an ischemic bowel with peritonitis
- Immediate jejunum and colon segmental resection with an ileotransverse colostomy was performed
- The further course of the treatment was characterized by severe sepsis with multiple organ failure and an excessive inflammatory response
- Antibiotic treatment with Linezolid (4 x 600 mg on day 1 continuing with 2 x 600 mg) and Meropenem (4 g/d) was started
- As the patient revealed a persisting excessive cytokine storm, a CytoSorb adsorber was applied

- At this time, the patient was treated with Linezolid and Meropenem intravenously by short duration infusions (15-60 min) and daily CytoSorb use

Treatment

- 4 sessions with CytoSorb were performed over a period of 96 hours
 - day 1: 7 h
 - day 2: 10 h
 - day 3: 8 h
 - day 4: 5 h

Measurements

- Analysis of antibiotic serum concentrations (i.e. Linezolid and Meropenem) to detect potential elimination by CytoSorb
- IL-6 elimination

Results

- Substantial reduction of IL-6 over the course of 4 CytoSorb treatments from 563,000 pg/ml on day 1 to 19,400 pg/ml on day 4
- High intra-patient variability for Linezolid and Meropenem levels was observed, which might be caused by adsorption effects by CytoSorb but also by the effects of critical illness
- By using a higher loading dose for Linezolid and Meropenem in this patient, all the antibiotic concentrations measured were sufficient and did not approach the lower limit of therapeutic level

Post-treatment period and follow-up

- After four weeks and seven re-laparotomies the patient died from multiple organ failure

Effects of CytoSorb use and antibiotic administration on serum concentrations of Interleukin-6 (IL-6), Linezolid and Meropenem

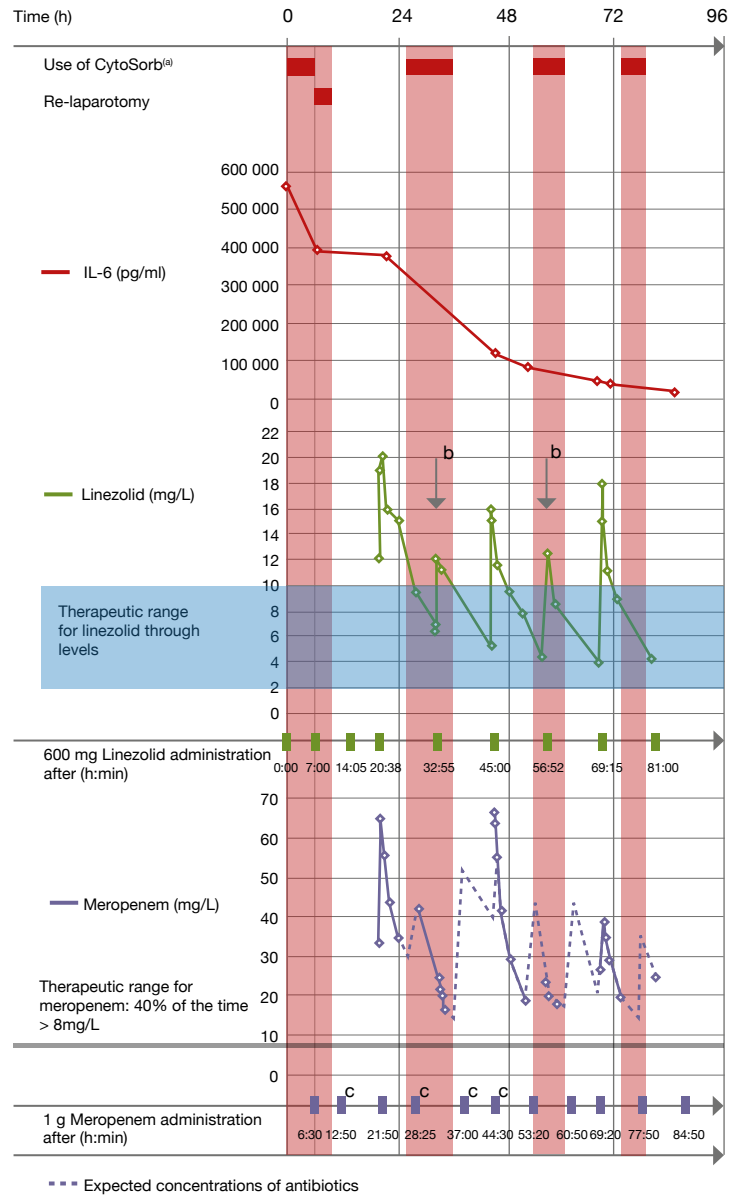


Figure 1. Effects of CytoSorb use and antibiotic administration on the serum concentrations of IL-6, linezolid and meropenem. The first 96 h after the start of CytoSorb use are shown.

^aUse of CytoSorb according to clinical decisions.

^bLower peak levels compared with adjacent peak levels.

^cAdministration of 2 g of meropenem.

CONCLUSIONS

- First time in vivo pharmacokinetic monitoring of Linezolid and Meropenem during treatment with CytoSorb
- Use of CytoSorb in this patient with severe septic shock proved to be sufficient (decay of IL-6) and safe (antibiotic levels well above the lower of therapeutic range)
- Using a high loading dose for Linezolid and Meropenem, antibiotic concentrations were always within the therapeutic range
- However, the results indicate that Linezolid and Meropenem serum concentrations might be reduced by use of CytoSorb
- In the absence of therapeutic drug monitoring, high loading doses and shorter intervals between antibiotic administrations could be used to achieve adequate antibiotic levels
- Further studies are necessary to understand the impact of CytoSorb on concentrations of different antimicrobials

Intermittent use of cytokine adsorption in combination with CRRT in a patient with necrotising pancreatitis, septic shock and MOF

Emmerich M, Zietlow S, Tiesmeier J

Institute for Anesthesiology and Intensive Care, Hospital Bad Oeynhausen, Germany

Infection. 2015 Aug;43 Suppl 1:1-73. Abstract No. 72

Summary

This case study reports on a 60-year-old female patient with septic shock and MOF after cholecystectomy which was complicated by massive aspiration and necrotizing pancreatitis. On admission to ICU, the patient was in respiratory and acute renal failure and exhibited high needs for vasopressors and fluids. Lung-protective ventilation and hemodynamic stabilization, antibiotic therapy and CRRT plus CytoSorb were started in the further course. During the first 48 h of hemoadsorption, norepinephrine requirements decreased markedly. During the second use of CytoSorb norepinephrine infusion could be stopped after 40 h. CRRT was stopped 11 days after the second CytoSorb treatment and two days later the patient was successfully weaned from ventilation. The authors conclude that they could successfully use intermittent cytokine hemoadsorption to manage a patient with recurrent septic shock, necrotising pancreatitis and MOF. Supplementing the standard treatment for sepsis with two applications of hemoadsorption facilitated rapid hemodynamic stabilization. CytoSorb was easy to use and no adverse effects were observed.

Case presentation

- A 60-year-old female patient with septic shock and MOF post-cholecystectomy complicated by massive aspiration during emergency gastroscopy and necrotising pancreatitis requiring necrosectomy
- On admission to ICU, the patient was in respiratory and acute renal failure with high needs for vasopressors and fluids
- Following initial stabilization, colonic perforation and renewed septic shock occurred on day 13 post-operation, necessitating colectomy and further necrosectomy on day 14

- Lung-protective ventilation and hemodynamic stabilization using nuanced fluid and norepinephrine therapy with advanced hemodynamic monitoring
- Antibiotic therapy was initiated with meropenem and linezolid administered in dosages adopted to CRRT
- CRRT (CiCa-CVVHD) was started on day 2 post-operation and combined with CytoSorb

Treatment

- 1st CytoSorb treatment beginning on the second post-operative day for 48 hours
- 2nd CytoSorb treatment from day 13 post-operation for 96 hours

Measurements

- Need for norepinephrine

Results

- During the first treatment, norepinephrine requirement decreased from 0.13 µg/kg/min to zero
- During the second treatment the initial norepinephrine need was 0.13 µg/kg/min which rose to a maximum of 0.43 µg/kg/min 12 h post-operatively
- However, the infusion could be stopped after 40 h

Patient follow-up

- The general condition of the patient improved dramatically despite further multiple operations for intra-abdominal bleeds, necrosis and wound healing impairment
- CRRT was stopped 11 days after the second treatment
- Two days later the patient was successfully weaned from ventilation

CONCLUSIONS

- Intermittent cytokine hemoadsorption could be successfully used to manage a patient with recurrent septic shock, necrotizing pancreatitis and MOF
- Supplementing the standard treatment for sepsis with two applications of hemoadsorption facilitated rapid hemodynamic stabilization
- CytoSorb was easy to use and showed no adverse effects

Case series of patients with severe sepsis and septic shock treated with a new extracorporeal sorbent

Laddomada T, Doronzio A, Balicco B
Anesthesia and Intensive Care Service, Policlinico San Marco, Zingonia, Italy
Critical Care 2016, 20(Suppl 2):P193

Summary

In this case series in 8 patients with severe sepsis and septic shock treated with CytoSorb the authors analyzed the impact of CytoSorb on clinical outcomes such as mean arterial pressure (MAP), vasopressors need and inflammatory markers, like procalcitonin (PCT). There was an overall improvement of MAP with a rapid reduction in vasopressor dosages. Moreover, CytoSorb treatment in combination with CRRT was associated with a marked decrease of PCT levels and an improvement in renal function. In non-survivors, MAP was hard to stabilize and decreased and there was an aggravation in overall patients' conditions. The authors conclude that a timely use of CytoSorb in combination with the standard therapy could have benefits in improving patients hemodynamics and helping a more rapid stabilization. However, more in vivo studies are needed to confirm these results.

Background

- Clinical studies have shown that the reduction of toxic levels of cytokines from blood with CytoSorb could be useful to regain control during a complicated inflammatory condition in patients with severe sepsis/septic shock
- In this case series, the authors evaluated patients admitted to ICU from Jan to Nov 2015 treated with CytoSorb
- The aim was to analyze the influence of CytoSorb on clinical outcomes, as mean arterial pressure (MAP), vasopressors need and inflammatory markers, like procalcitonin (PCT)

Methods

- 8 patients (4 f, 4 m) were included: 2 with severe sepsis and 6 with septic shock
- All patients were not responding to the Standard of Care for the treatment of severe sepsis/septic shock
- Therefore, CytoSorb was used as adjunctive therapy in combination with continuous renal replacement therapy (CRRT), in order to control the cytokine storm and improve the hemodynamic stability
- CytoSorb was installed in series connection after the dialyzer in the CRRT circuit for 24 h each (median duration of the treatment: 48 h)
- Clinical parameters were collected before and after every treatment with CytoSorb

Results

- Six treated patients survived
- During the treatment there was an overall improvement of MAP
- This was paralleled by a rapid reduction in vasopressor dosages: noradrenaline decreased from 0.33 to 0.13, and dopamine from 7.5 to 3 µg/kg/min
- Moreover, there was a marked decrease of PCT levels from 14.53 to 3.90 ng/dl and an improvement in renal function
- In non-survivors, MAP was hard to stabilize and decreased in the further course and there was an aggravation in overall patients' conditions

CONCLUSIONS

- To the authors experience, a timely use of CytoSorb in combination with standard therapy could have benefits in improving hemodynamics and help to more rapidly stabilize patients with septic shock
- However, more in vivo studies are needed to confirm these results

Treatment of post-cardiopulmonary bypass SIRS by hemoadsorption: A case series

Träger K, Fritzer D, Fischer G, Schröder J, Skrabal C, Liebold A, Reinelt H.
Department of Cardiac Anesthesiology, University Hospital Ulm, Germany
Int J Artif Organs. 2016 May 16;39(3):141-6.

Summary

Objective of this case series in 16 adult patients undergoing standard or emergency cardiothoracic surgery procedures with prolonged CPB time, developing post-CPB SIRS over the course of the first post-operative 24 hours was to test the effect of CytoSorb on changes of inflammatory cytokines levels, metabolic parameters hemodynamic variables, and patient outcome. Treatment of these patients with CytoSorb in conjunction with CVVHD was associated with decreases in the proinflammatory cytokines, IL-6 and IL-8, as well as a clear stabilization of hemodynamic, metabolic and organ function parameters. All patients with an APACHE score of up to 30 survived. This is the first case series reporting the use of CytoSorb therapy in patients with post-CPB SIRS. Due to a modulation of the cytokine response, CytoSorb may offer a potentially promising new treatment option for severe post-CPB SIRS that presents with hemodynamic instability and requires high doses of vasopressors.

Objective

- To test CytoSorb on changes of inflammatory cytokines levels, metabolic parameters hemodynamic variables, and patient outcome

Design / patients

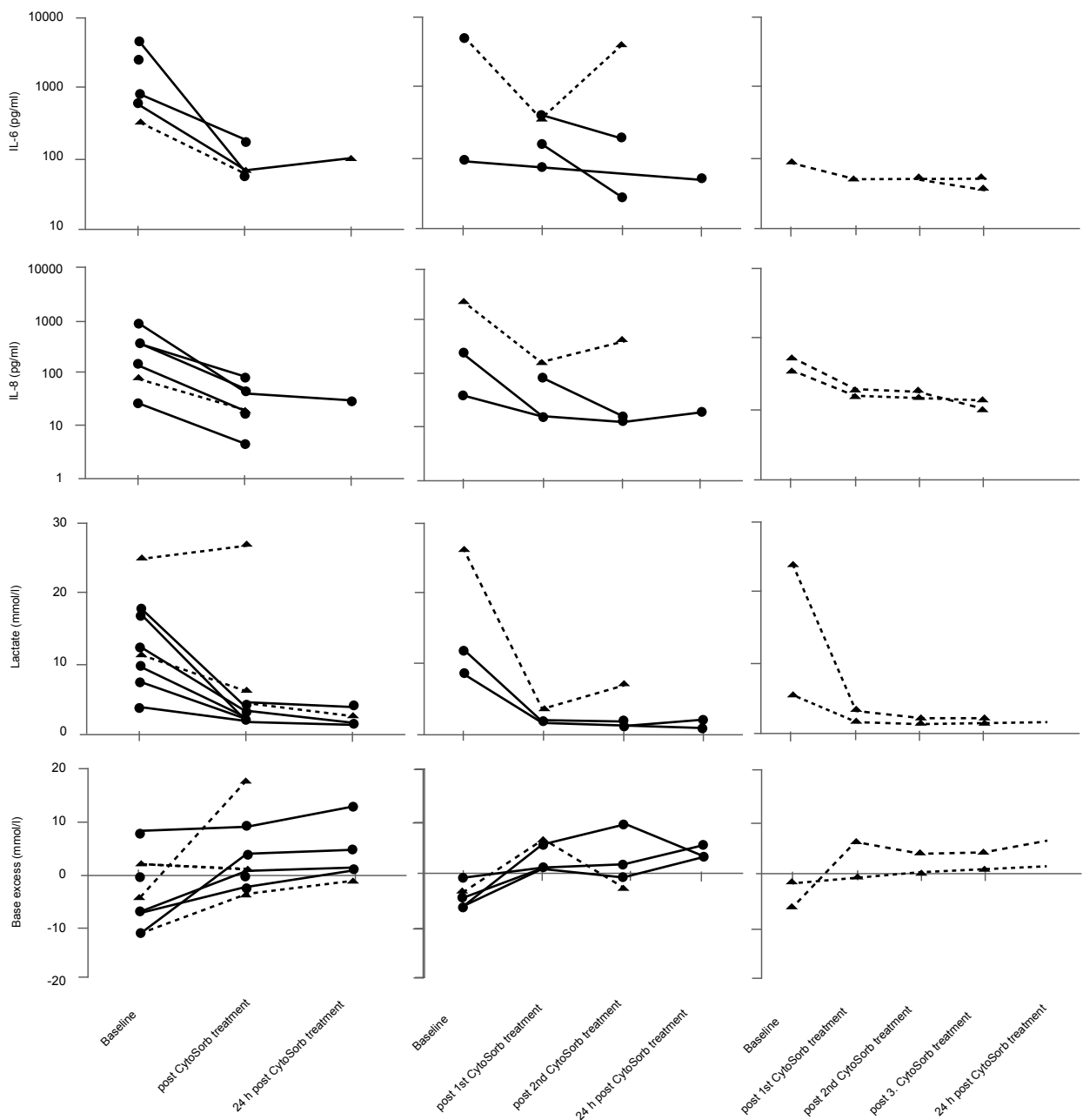
- Case series in 16 adult patients undergoing standard or emergency cardiothoracic surgery procedures with prolonged CPB time, developing post-CPB SIRS over the course of the first post-operative 24 hours
- All of the patients received CRRT for treatment of acute kidney injury

CytoSorb treatment

- Use of CytoSorb in combination with CRRT performed in CVVHD mode using a citrate-based anticoagulation protocol (Multifiltrate CiCa, Fresenius Medical Care) and systemic heparin or argatroban anticoagulation was supplemented when demanded for clinical reasons
- Blood flow rates: 100 to 140 mL/min
- Minimum of 1 CytoSorb treatment and additional treatments depending on clinical response (start of subsequent treatments within 48 hours after termination of the previous session)

Results

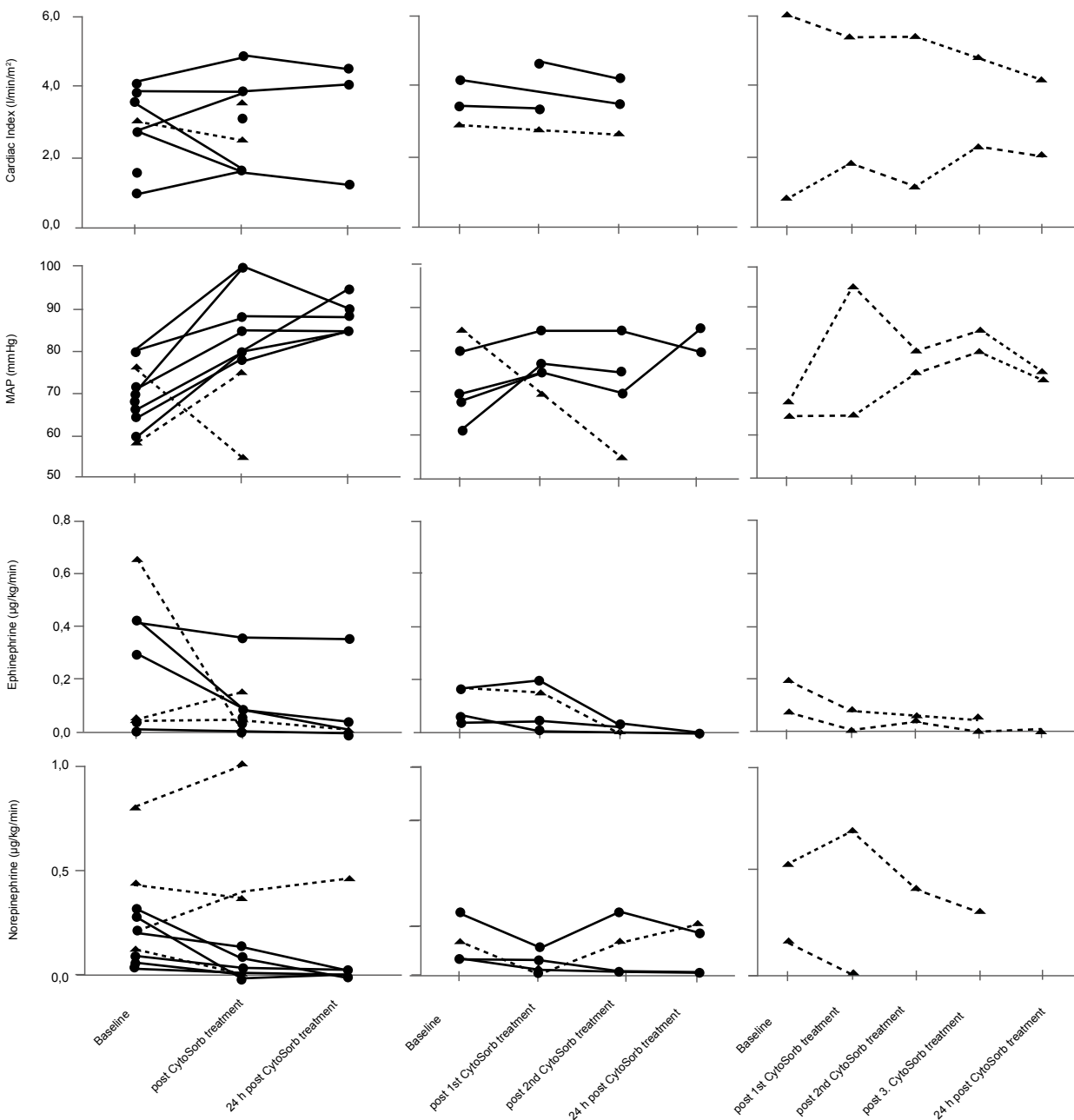
- Marked decrease in levels of IL-6 and IL-8 persisting at low levels even beyond 24 hours after termination of treatment
- Stabilization of hemodynamic parameters as demonstrated by a rise in MAP and improvement in CI with a concomitant reduction of catecholamines (epinephrine and norepinephrine)
- In most cases, vasopressor dosages could be reduced within 12 hours of treatment with CytoSorb with even clearer reductions by 24 hours, which was more sustained in the survivor group
- Nonsurvivors required generally higher levels of vasopressors at baseline, consistent with the severity of illness predicted by the APACHE 2 score
- No recurrence of hypotension and no increased need for vasopressors 24 hours after termination of CytoSorb treatment
- Deranged metabolic parameters (i.e., lactate, base excess) were generally normalized during and after the treatment period
- Trend of SOFA scores towards improvement during treatment that generally persisted 24 hours after the last treatment
- 10 (of 16) patients were alive at day 28 (survival rate 62.5 %), with a survival of all CytoSorb-treated patients with an APACHE 2 score of up to 30
- CytoSorb was well tolerated, with no specific device-related adverse events during or after treatment. The device was easy to implement as part of the CRRT circuit. In particular, no clotting issues of the CytoSorb device were observed with the use of citrate anticoagulation



Levels of IL-6 and IL-8 as well as metabolic parameters, including lactate and base excess, throughout the treatment period. From left to right images for each parameter display patients receiving 1 (left), 2 (middle) or 3 (right) treatments, respectively. Values were assessed directly prior to treatment (baseline), immediately after termination of each treatment (post CytoSorb) and 24 hours after termination of the last treatment (24 hours post CytoSorb). Solid lines indicate 28-day survivors, dashed lines represent nonsurvivors. Please note that some parts of the data were not available from all patients.

CONTINUATION: Treatment of post-cardiopulmonary bypass SIRS by hemoadsorption: A case series

Träger K, Fritzer D, Fischer G, Schröder J, Skrabal C, Liebold A, Reinelt H.
 Department of Cardiac Anesthesiology, University Hospital Ulm, Germany
Int J Artif Organs. 2016 May 16;39(3):141-6.



Hemodynamic variables, including cardiac index, mean arterial pressure and catecholamine doses, throughout the treatment period. From left to right images for each parameter display patients receiving 1 (left), 2 (middle) or 3 (right) treatments, respectively. Values were assessed directly prior to treatment (baseline), immediately after termination of each treatment (post CytoSorb) and 24 hours after termination of the last treatment (24 hours post CytoSorb). Solid lines indicate 28-day survivors, dashed lines represent nonsurvivors. Please note that parts of the data were not available from all patients.

Case No	Age (years)	Gender	BMI	CPB time (min)	x clamp time (min)	Type of surgery	Emergency	CytoSorb treatments (n)	CytoSorb treatment time (h)	Hydro-cortisone	APACHE II base-line	Outcome ICU	28 day survival
1	68	M	34.1	107	56	MV replacement	Yes	1	29	Yes	29	Surv	Yes
2	78	M	25.9	120	80	MV repair	No	1	29	Yes	25	Surv	Yes
3	69	M	29.8	235	157	ascending aorta repair. AV replacement	No	1	32	Yes	18	Surv	Yes
4	63	M	34.4	134	81	AV replacement. CABG	No	1	41	Yes	27	Surv	Yes
5	81	M	28.7	191	139	CABG. MV repair. TV repair. aortic root repair	No	1	33	Yes	24	Surv	Yes
6	75	M	28.7	214	116	ascending aorta and aortic arch replacement	Yes	1	38	No	47	Died	No
7	75	M	23.9	120	67	MV replacement. TV repair	No	3	38, 25, 25	Yes	32	Died	No
8	62	F	20.2	132	82	MV repair. TV repair	No	2	39,41	No	24	Surv	Yes
9	73	M	43.2	112	58	ascending aorta and aortic arch repair	No	2	45, 26	No	34	Died	No
10	53	M	39.6	392	247	ascending aorta replacement. David surgery	Yes	2	33, 36	No	22	Surv	Yes
11	77	F	27.2	327	178	Redo ascending aorta replacement. AV replacement. CABG	No	3	44, 2, 39	Yes	29	Died	No
12	74	M	37.4	348	168	ascending aorta replacement. AV replacement	No	2	29, 24	No	24	Surv	Yes
13	84	M	24.8	230	157	AV and MV replacement. CABG	Yes	1	36	No	36	Died	No
14	55	M	30.8	226	104	ascending aorta repair	Yes	1	34	No	28	Surv	Yes
15	77	F	19.7	236	125	ascending aorta and aortic arch repair	No	1	50	Yes	23	Surv	Yes
16	73	F	25	422	112	Aortic root replacement. CABG	Yes	1	5	Yes	36	Died	No

Patient characteristics, surgery details, treatment modalities and patient outcome

Case No	Crea before start of CRRT $\mu\text{mol/l}$	Urea before start of CRRT mmol/l	Diuresis before start of CRRT	AKIN stage at CRRT start	Delivered dialysis dose ml/kg/h	No. of CRRT sessions	Details on renal outcome/recovery on ICU	Days on CRRT	Heparin yes / no	Citrate yes / no
1	305	24.5	730 ml / 6 h	II	19	1	recovery	4	no	yes
2	176	9.5	160 ml / 6 h	I	24	1	recovery	4	yes	yes
3	210	8.4	830 ml / 6 h	I	20	1	recovery	3	no	yes
4	240	8	155 ml / 6 h	I	18	2	recovery	7	yes	yes
5	187	15.2	135 ml / 6 h	I	22	5	non-recovery	18	no	yes
6	137	13.9	890 ml / 6 h	I	23	1	non-recovery	2	no	yes
7	148	7.9	130 ml / 6 h	II	25	7	non-recovery	24	no	yes
8	118	17.9	120 ml / 3 h	II	29	5	non-recovery	17	no	yes
9	280	12.9	anuria	III	21	1	non-recovery	3	no	yes
10	166	6.9	120 ml / 6 h	II	18	2	recovery	7	no	yes

CRRT details & renal outcome

CONCLUSIONS

- This is the first case series reporting the use of CytoSorb therapy in patients with post-CPB SIRS
- Treatment of such patients with CytoSorb in conjunction with CVVHD was associated with decreases in the proinflammatory cytokines, IL-6 and IL-8, as well as a clear stabilization of hemodynamic, metabolic and organ function parameters. All patients with an APACHE score of up to 30 survived
- CytoSorb therapy in these patients was easy and safe to use, and there were no device-related adverse events reported
- Due to a modulation of the cytokine response, CytoSorb may offer a potentially promising new treatment option for severe post-CPB SIRS that presents with hemodynamic instability and requires high doses of vasopressors

Systemic Inflammatory Response Syndrome in Cardiac Surgery: New possibilities for treatment through the use of a cytokine adsorber during ECC?

[Systemic Inflammatory Response Syndrome in der Herzchirurgie: Neue Therapie-möglichkeiten durch den Einsatz eines Cytokin-Adsorbers während EKZ?]

Born F, Pichlmaier M, Peterß S, Khaladj N, Hagl C
Department of Cardiac Surgery, Ludwig-Maximilians University, Munich, Germany
Kardiotechnik 2/2014

Summary

The occurrence of the systemic inflammatory response syndrome (SIRS) is one of the most significant complications after cardiosurgical operations with the application of a Cardio-Pulmonary-Bypass (CPB). In this retrospective observational case series in 40 patients undergoing a major cardiosurgical procedure using CPB the hypothesis was tested, whether the intraoperative treatment with CytoSorb could have a positive effect on the post-operative laboratory markers for SIRS. Results show, that CytoSorb contributes to a significant reduction of markers of post-operative SIRS in those patients. This case series emphasizes the reliability and safety of CytoSorb also in the setting of cardiac surgery.

Case series presentation

- 40 patients undergoing a major cardiosurgical procedure with the application of CPB
- n = 20 with CPB, n = 20 with CPB + additionally implemented CytoSorb
- Retrospective analysis

Treatment

- Cardiac surgery using standard CPB protocol
- Intraoperative application of CytoSorb in treatment group (CS) for the entire time of operation

Measurements

- Blood samples were drawn from the patients immediately after the operation and 1-3 days post-operatively
- Measured parameters were C-reactive protein, procalcitonin, leucocytes, fibrinogen, IL-6

Results

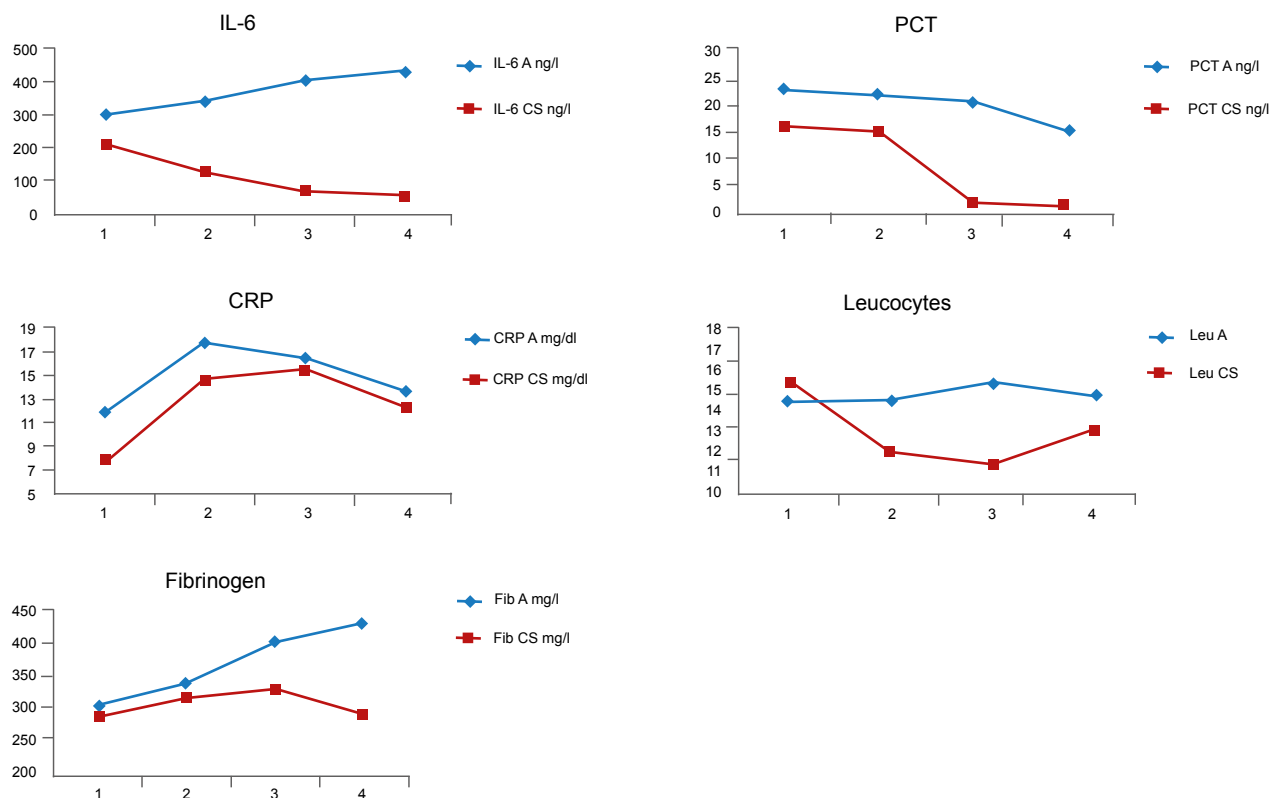
- Treatment with CytoSorb had a direct and positive effect on the laboratory markers of post-operative SIRS
- There were significant differences in the inflammation parameters between the two groups immediately following surgery
- Interleukin-6: During the post-operative period, IL-6 was moderately elevated in the CytoSorb group and reached normal levels again over the course of the following 3 days. In the control group, IL-6 levels were already elevated post-operatively, and showed a trend that continues to increase further
- Fibrinogen: In the CytoSorb group, values for fibrinogen consistently remained within the normal range during the post-operative period and began to drop after the third post-operative day. In contrast, levels in the control group rose significantly above the upper threshold value of the normal laboratory range and continued to increase further after day 3
- Leukocytes: Leukocytosis developed in both groups immediately after the operation was finished. In the further course, leukocyte counts decreased faster with CytoSorb and remained below the leukocyte count of the control group for the entire observation period
- C-reactive protein: During the 3 post-operative days, CRP levels returned to a near physiological normal level in both groups. However, the increase in the CytoSorb group was less pronounced and normalization occurred more rapidly when compared to the control group
- Procalcitonin: The increase in procalcitonin was significantly less pronounced using CytoSorb therapy compared to the control group and the difference was highly significant at all measurement time points. In addition, the PCT decreased more quickly in the CytoSorb group throughout the post-operative period when compared to control

Statistical evaluation of the post-operative profile of inflammatory parameters in both groups

(s.=significant;
n.s.=not significant;
h.s.=highly significant)

CS Group vs A Group	postop (1)	1 st day (2)	2 nd day (3)	3 rd day (4)
IL-6	s. p = 0.033	s. p = 0.031	h.s. p = 0.004	h.s. p = 0.005
Fib	n.s. p = 0.657	n.s. p = 0.550	n.s. p = 0.151	s. p = 0.019
Leu	n.s. p = 0.788	n.s. p = 0.652	n.s. p = 0.536	n.s. p = 0.234
CRP	s. p = 0.028	n.s. p = 0.079	n.s. p = 0.747	n.s. p = 0.516
PCT	h.s. p = 0.008	h.s. p < 0.002	h.s. p < 0.001	h.s. p < 0.001

Post-operative profile of inflammatory parameters in the two groups (A = control, CS = CytoSorb)



CONCLUSIONS

- The data demonstrate the reliability and safety of the new CytoSorb therapy in the area of cardiac surgery
- Intra-operative use of CytoSorb during open heart surgery with application of CPB has a positive effect on clinical and inflammatory parameters of post-operative SIRS
- If results can be confirmed in a prospective controlled trial, CytoSorb could be established as a routine application in cardiac surgery

Application of Hemoadsorption in a Case of Liver Cirrhosis and Alcohol-Related Steatohepatitis with Preexisting Hepatitis C Infection

^aBüttner S, ^aPatyna S, ^aKoch B, ^bFinkelmeier F, ^aGeiger H, ^bSarrazin C, ^bFarnik H

^aDepartment of Nephrology, Medical Clinic III, University Hospital Frankfurt, and

^bDepartment of Gastroenterology and Hepatology, Medical Clinic I, University Hospital Frankfurt, Frankfurt, Germany

Blood Purif 2017; 44(1): 30-31

Summary

In this case a 36 year old male with a history of chronic alcohol abuse and hepatitis C was admitted with alcohol induced decompensated toxic liver cirrhosis. After a month long stay in ICU, the patient was rejected from the liver transplant list. As his condition failed to improve, continuous renal replacement therapy (CRRT) was started along with CytoSorb in an attempt to remove inflammation triggering factors and liver toxins. During the first treatment, renal function and diuresis improved rapidly. Kinetic pre and post adsorber measurements during the second treatment 5 days later confirmed efficient removal of ammonia, bilirubin and bile acids, accompanied by a significant clinical improvement in his hepatic encephalopathy. Unfortunately, after a very positive course and plans already initiated for his discharge, he went on to develop pneumogenic sepsis and died.

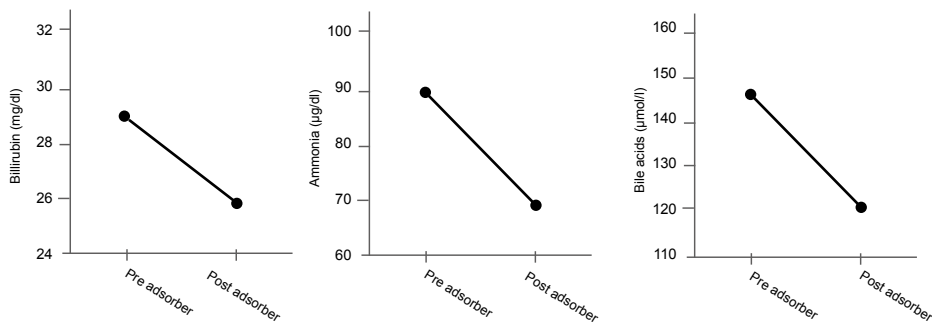
Case presentation

- 36-year-old patient (chronic viral hepatitis C, longtime chronic alcohol abuse up to the point of admission to hospital) was transferred from an external hospital with decompensated ethanol toxic liver cirrhosis.
- Direct admission of the patient to the intensive care unit
- At this point the patient was hypotonic, tachycardic, in cardiogenic shock, oliguric, with upper gastrointestinal bleeding and a MELD score of 40
- Development of hepatic encephalopathy
- Attempt to stabilize the patient using albumin infusion and multiple paracenteses
- Diagnosis of hepatorenal syndrome due to decompensated cirrhosis and subsequent dialysis dependency
- Portal vein thrombosis was excluded
- Consequently the patient was treated for more than a month in the intensive care unit to stabilize the cirrhosis and acute kidney injury
- During this time, an evaluation as to whether the patient could be listed for a liver transplantation or not was rejected by the Liver Board due to the ongoing alcohol abuse up to the point of admission to ICU

- Since no transplant option existed, physicians continued therapy with available treatment options. The patient received steroid therapy with 40 mg per day, however this did not result in any significant improvement
- Plasma bilirubin concentrations showed a significant increase of up to 24.5 mg/dl, ammonia levels were 130 µg/dl, albumin was 2.4 g/dl
- In addition, transaminases (GOT 259 U/L, GPT 59 U/L) as well as GGT (352 U/L) were markedly elevated
- Markers for spontaneous coagulation at this time were also poor with a Quick of 26%, Antithrombin III of 49%, PTT 42, INR 2.87
- Inflammation markers were: leukocytes 43,000/µl, CRP low at 3.46 mg/dl, and IL-6 42 pg/ml
- During this phase, the patient received a low-dose norepinephrine infusion (<0.025 µg/kg/min)
- As a „last resort“ therapy, and due to a lack of clinical improvement, CytoSorb treatment was started with the rationale to remove inflammation-triggering factors and liver toxins (bile acids, bilirubin, ammonia) in the context of his systemic inflammatory condition as well as his acute-on-chronic liver failure
- Subsequent final diagnosis: Liver cirrhosis and alcohol-related steatohepatitis (ASH) with pre-existing hepatitis C infection

Treatment

- In total two treatments with CytoSorb were carried out, 1st treatment for 6 hours, followed by a treatment pause for 5 days to wait for the therapy effect due to non-existing evidence in this kind of patient, 2nd treatment for 6 hours
- 1st CytoSorb was performed in conjunction with CRRT (Multifiltrate, Fresenius Medical Care) performed in CVVHDF mode, 2nd treatment was performed in hemoperfusion mode
- Blood flow rate: 200 ml/min
- Anticoagulation: Heparin
- CytoSorb adsorber position: pre-hemofilter



Kinetic pre and post adsorber measurements during the second (hemoperfusion mode only without CVVHD) treatment showing an efficient removal of bilirubin, ammonia and bile acids by the CytoSorb adsorber.

Measurements

- Ammonia (pre/post adsorber)
- Bilirubin (pre/post adsorber)
- Bile acids (pre/post adsorber)
- Inflammatory parameters (IL-6, CRP, leucocytes)

Results

- After the first treatment ammonia reduced to 88 µg/dl. During the 2nd treatment ammonia levels were measured pre and post adsorber: pre-adsorber 89 µg/dl - directly post adsorber 70 µg/dl; two hours later and also during treatment 2 ammonia levels pre-adsorber were 76 µg/dl and directly post adsorber 60 µg/dl, patient significantly improved both during and after the treatment sessions
- Reduction of bilirubin in the course of the first treatment from 24.5 mg/dl to 16.3 mg/dl after 4 hours (thereafter no further reduction, probably due to saturation of the adsorber), between the 1st and 2nd treatment bilirubin rose to 31.5 mg/dl. During the 2nd treatment session levels reduced again to 25.9 mg/dl within 4 hours
- Measurement of bile acids pre and post adsorber during the 2nd treatment were as follows: pre-adsorber 145 µmol/l – directly post-adsorber 119.7 µmol/l

- Increase of IL-6 during the first hour of the first treatment to 255.7 pg/ml (suspected catheter-associated infection, however with no subsequent successful pathogen detection), in the further course during the first treatment reduction to 33.5 pg/ml, no more valid measurement performed during 2nd treatment
- Leucocytes continuously reduced during both treatments to 20,000/µl after the first and 15,000/µl after the second treatment
- CRP was continuously low between 2-4 mg/dl during both treatment cycles
- During the first treatment, renal function and thus diuresis improved rapidly, so that CVVH could be discontinued after the first treatment

Patient follow-up

- Termination of renal replacement therapy directly after the first CytoSorb session with stable diuresis and stable creatinine
- Patient with initially good clinical recovery and planned discharge to his home environment due to the lack of a transplant option
- Subsequent development of a nosocomial pneumonia, after which the patient went into an episode of fulminant pneumogenic sepsis and died three weeks after the last CytoSorb treatment

CONCLUSIONS

- CytoSorb represents a good and viable treatment option for patients with alcoholic steatohepatitis (ASH) and may be especially effective in young patients with severe inflammatory response in the context of their ASH
- CytoSorb worked extremely well and effectively as a liver replacement in this case, hepatic encephalopathy improved significantly due to removal of liver toxins
- In addition, measurement of pre/post adsorber values indicates that the removal of ammonia, bilirubin and bile acids is directly attributable to the adsorber
- According to the medical team, the impressive course of the patient has led to the initiation of a specific study project for such patients
- The installation of the adsorber into the CVVH circuit and the application of CytoSorb itself was easy and safe

Hemoadsorption with Adult CytoSorb® in a Low Weight Pediatric Case – A Worldwide Premiere Procedure

Cirstoveanu C^{1,2}, Barascu I², Stancu A.¹

¹ Carol Davila University of Medicine & Pharmacy Bucharest, Romania,

² Marie S. Curie Children's Emergency Hospital Bucharest, Neonatal Intensive Care Unit, Romania
Case Rep Crit Care. 2017;2017:6987167

Summary

This case study describes a nine-month old male infant admitted to the Neonatal Intensive Care Unit due to sepsis post cardiac surgery (Fallot tetralogy), and multi-system organ failure (MSOF), including liver and renal failure which was successfully treated by a combination of continuous hemodiafiltration (HDF) and hemoadsorption with CytoSorb®. CytoSorb was added to the set up on day 9 due to increasing bilirubin levels. Over the 49 hour period of hemoadsorption plus CytoSorb, total bilirubin decreased from 54 to 14 mg/dl, the patient's general status improved considerably, accompanied by a rapid decrease in his liver enzymes (aminotransferases). Hemodynamic status also improved and requirement for inotropes decreased rapidly during the two days of CytoSorb treatment. The patient was discharged home after 34 days of hospitalization, in good general health. This is the first published case of the successful use of CytoSorb treatment in such a young patient (9 months old, 9 kilos in weight).

Case presentation


- A nine-month old, 9 kg male infant was admitted to Cardiovascular Surgery for correction of Tetralogy of Fallot. He was extubated on postop day 1, but re-intubated on day 2 because of pleural and peritoneal effusions
- On the 3rd postop day the patient became febrile, so a complete blood count (CBC), biochemistry and a blood culture were performed. On day 4 he was admitted to the NICU gravely unwell, intubated and mechanically ventilated, with unilaterally diminished breath sounds, hypoxemia (oxygen saturation: 90%), oliguria, tachycardia (137 beats per minute), hypotension (74/44/59 mmHg) and abdominal distention with anasarca and fever (39-40°C). Physical examination revealed hepatosplenomegaly
- CBC showed hemoconcentration (Hb: 14.2 g/dl, Ht: 45%), thrombocytopenia (27,000/mm³), leukocytosis (17,800/mm³) with neutrophilia (66.6%). Coagulation tests revealed a grossly elevated INR (4.66), hypofibrinogenemia (113 mg/dl) and a prolonged aPPT time (63 seconds). A severe inflammatory response (SIRS) was noted (CRP: 47.76 U/L, Procalcitonin: 10 ng/L). Liver function tests (LFTs) were greatly abnormal (ALT: 1883.1 U/L, AST: 4214.5 U/L, GGT 72 U/L, total bilirubin: 10.05 mg/dl, direct bilirubin: 7.59 mg/dl), consistent with hepatocellular necrosis
- Renal impairment was evident with a creatinine of 1.15 mg/dl and urea of 55 mg/dl. Creatinine kinase

and creatine kinase-MB were also elevated with values of 1619 U/L and 159.6 U/L, respectively. Acid-base balance was deranged (metabolic acidosis). Blood culture was sterile and the culture from tracheal aspirate revealed *Escherichia coli*

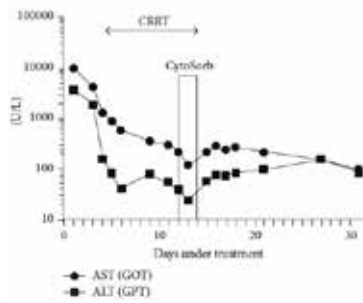
- Meropenem, Vancomycin and Fluconazole were initiated. Multiple episodes of severe hypotension and bradycardia were treated with adrenaline, noradrenaline and dopamine. Due to persistent SIRS (CRP values from 47.76 to 54.76), antibiotics were changed to Tienam (Imipenem and Cilastin) and Amikacin
- Two days after ICU admission oliguria rapidly evolved to anuria, and peritoneal dialysis was initiated. While the patient's fluid intake continued to exceed the output the decision was made to start hemodiafiltration (HDF) (Prismaflex, Baxter). Throughout HDF, the patient continued to be hypotensive and bradycardic necessitating an increased dose of inotropic agents
- Metabolic acidosis also persisted despite treatment, he continued to be thrombocytopenic requiring multiple thrombocyte mass transfusions. He also developed macrocytic, hyperchromic anemia. After initiation of HDF he continued to be oliguric with intensely hyperchromic hematuria
- As the patient continued to be febrile, antibiotic therapy was modified once more to Meropenem and Ciprofloxacin for a duration of 16 days. Antibiotic doses were kept constant throughout the treatment
- Bilirubin levels kept increasing, culminating in a maximum value of 54 mg/dl of total bilirubin and 31.67 mg/dl of direct bilirubin. Intense scleral and cutaneous jaundice was observed and the patient was diagnosed with cholestatic jaundice
- On the 9th day of continuous hemodiafiltration the therapeutic decision of commencing hemadsorption with a cytokine adsorber (CytoSorb) was taken

Treatment

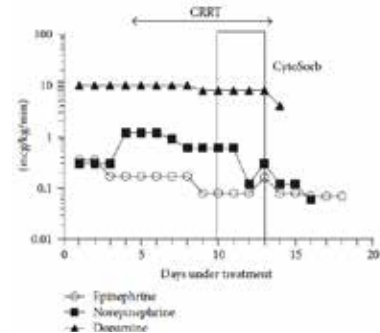
- One treatment with CytoSorb for 49 hours
- CytoSorb was used in conjunction with CRRT (Prismaflex, Baxter) performed in CVVHDF mode
- Blood flow rate: 40 ml/min
- Because of the flow rate being so much slower than the recommended flow rate, the procedure was maintained for 49 hours
- Anticoagulation: Heparin
- CytoSorb adsorber position: post-hemofilter



Level of total and direct bilirubin 48 hours before CytoSorb during, and 48 hours after treatment



Level of aminotransferases 48 hours before CytoSorb during, and 48 hours after treatment



Catecholamine doses pre, during and 48 hours after CytoSorb.

Measurements

- Demand for catecholamines (norepinephrine, dopamine, epinephrine)
- Ventilation settings (FiO₂, respiratory rate, positive end expiratory pressure (PEEP), positive inspiratory pressure (PIP))
- Bilirubin, transaminases

Results

- During the first 24-hour period with CytoSorb, total bilirubin value decreased from 54 to 17 mg/dl and the patient's general status improved considerably. At the end of the 49 hours the total bilirubin was 14 mg/dl.
- The liver enzymes (aminotransferases) also decreased rapidly but rose to their previous values as soon as CytoSorb was removed
- Noradrenaline decreased rapidly from 0.8 to 0.18 mcg/kg/min during the first 24 hrs and ceased within the next 24 hours. Dopamine decreased from 8 to 5 mcg/kg/min to 0 during liver support. The dose

of adrenaline decreased within 48 hours of CytoSorb treatment and ceased after 5 days

- The patient's ventilation settings also improved during CytoSorb treatment

Patient follow-up

- HDF was stopped after 11 days
- The patient's cardiovascular status improved
- Diuresis gradually reached normal values and enteral nutrition could be initiated
- Quantitative renal function returned to normal as did renal function tests
- It was possible to keep the antibiotic doses constant during the entire CytoSorb procedure
- The patient was discharged home after 34 days of hospitalization, in good general status, hemodynamically stable, afebrile and weighing 9.6 kilograms
- He was referred to a pediatric neurologist for follow-up

CONCLUSIONS

- This is the first published case of CytoSorb used in a critically unwell 9 month old baby
- CytoSorb could be safely used in this pediatric case of septic multi-organ failure after cardiac surgery
- Both bilirubin levels and liver enzymes improved dramatically during CytoSorb use as did the patients hemodynamic and respiratory status
- Despite the fact that the flow rate was only 40 mls/min (normally >100-150 mls/min), there were no instances of clotting in the adsorber
- Antibiotic doses could be kept constant during the entire hemoadsorption procedure using CytoSorb

First report of cytokine removal using CytoSorb in severe non-infectious inflammatory syndrome after liver transplantation

Tomescu DR, Dima SO, Ungureanu D, Popescu M, Tulbure D, Popescu I
 Department of Anesthesiology and Critical Care III, Fundeni Clinical Institute, Bucharest, Romania
Int J Artif Organs 2016; 39(3): 136 - 140

Summary

In this report the authors present the case of a 46-year-old man with primary graft nonfunction after liver transplantation who underwent emergency retransplantation with an ABO-incompatible graft. A severe inflammatory response syndrome (SIRS) was noted in the perioperative period of retransplantation. The patient was successfully treated for this condition with CytoSorb in combination with CVVH throughout the intraoperative and early postoperative period. During and after each treatment a significant and rapid decrease of pro- and anti-inflammatory cytokines was observed (IL-6, IL-10, MCP-1). Reduction of cytokines was associated with normalization of cardiac output, systemic vascular resistance, and improved liver function. The authors believe this is the first case in which hemoadsorption in combination with CVVH has been used to manage SIRS in a patient with primary graft nonfunction undergoing emergency retransplantation.

Case presentation

- 46-year-old man who was undergoing deceased donor liver transplantation (LT) for Hepatitis-B-Virus (HBV) and alcoholic cirrhosis
- Postoperatively, the patient remained neurologically unresponsive, could not be extubated, and there was a massive increase in serum transaminases and bilirubin
- Hyperdynamic hemodynamic status with a high cardiac index (CI) and low systemic vascular resistance index (SVRI) requiring vasopressor support was noted immediately after surgery
- Laboratory results showed disseminated intravascular coagulopathy and one session of plasma exchange was performed for severe coagulopathy and cholestasis
- Acute graft dysfunction was diagnosed on the 1st postoperative day with emergency retransplantation (ABO incompatible) 36 hours after the first LT

Treatment

- CytoSorb was used in conjunction with CVVH during retransplantation for the entire duration of surgery (total treatment time of 7 hours) and on the first postoperative day with a treatment time of 12 hours

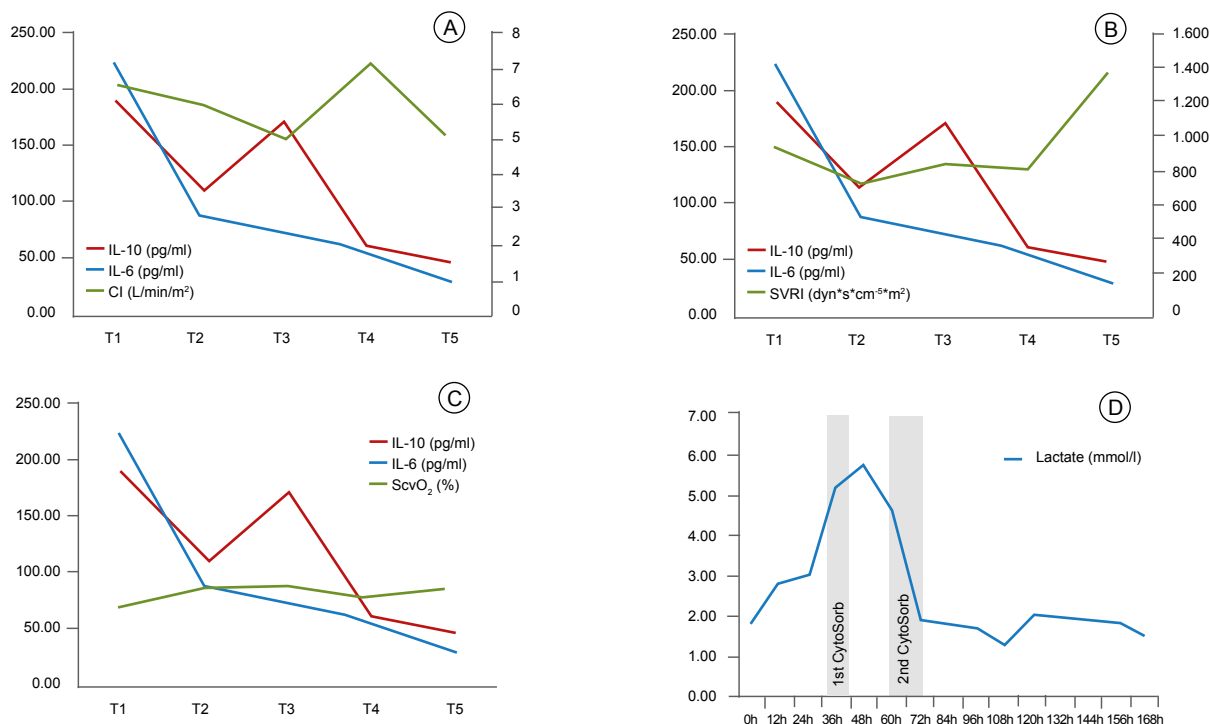
- CytoSorb was installed into the CVVH circuit (MultiFiltrate® using an Ultraflux® AV 600S hemofilter, Fresenius Medical Care)
- Blood flow rates were 150 ml/min
- Anticoagulation was achieved using heparin
- Intraoperative immunosuppression consisted of 500 mg methylprednisolone and 20 mg basiliximab

Measurements

- Cytokine levels were measured at the beginning of surgery (T1), after graft reperfusion (T2), at the end of surgery (T3) and before (T4) and after (T5) the second CytoSorb treatment
- Hemodynamic parameters, biochemical assays and vasopressor support were noted

Results

- During the first treatment proinflammatory cytokines IL-1 β , TNF- α , IL-6 and IL-8 levels decreased, antiinflammatory cytokines IL-4, IL-13 were constant within the normal range, IL-10 and MCP-1 levels decreased 10-fold to about normal levels
- Improvement in hemodynamics with a stabilized MAP and a continuous decrease in vasopressor support (NE) during surgery (NE discontinued at the end of surgery)
- The use of CytoSorb during the second session was associated with an improvement in cardiac output and SVRI
- Lactate levels and central venous oxygen saturation (ScvO₂) returned to normal values
- A decrease in platelet count was observed during both treatments (attributed to a multifactorial etiology: CVVH procedure, use of heparin, intraoperative blood loss, and possibly to the use of CytoSorb)
- The treatment was well tolerated with no obvious adverse effects



Improvement in hemodynamic parameters observed during the use of CytoSorb: cardiac index (A); systemic vascular resistance (B); and central venous oxygen saturation (C) remained constant intraoperatively and returned to normal values after the second CVVH CytoSorb treatment; trend of lactate (D) after liver transplantation (LT), during and after retransplantation (rLT) – including treatments with CVVH/CytoSorb

Patient follow-up

- Patient was extubated 12 hours after re-transplantation
- Liver function returned to normal within the next 5 days
- Discharge from the Post Anaesthesia Care Unit 7 days after retransplantation
- Discharge from hospital on the 35th postoperative day
- At the 4 month follow-up the patient was in good clinical state with normal liver function
- A normal liver function was also recorded at the 1-year follow-up

CONCLUSIONS

- First use of CytoSorb during CVVH in a patient undergoing re-transplantation with ABO incompatible graft for Acute Graft Dysfunction
- The use of CytoSorb was associated with an excellent outcome in terms of improved hemodynamic parameters, rebalancing proinflammatory and antiinflammatory cytokines, and patient survival to hospital discharge
- Observation suggests a shift from a SIRS state to a more balanced inflammatory response syndrome
- Hemoadsorption with CytoSorb may represent an approach to bridge patients with acute liver failure or Acute Graft Dysfunction to liver transplantation

First description of SPAD combined with cytokine adsorption in fulminant liver failure and hemophagocytic syndrome due to generalized HSV-1 infection

Frimmel S, Schipper J, Henschel J, Tsui TY, Mitzner SR, Koball S.
Division of Nephrology, Department of Medicine, Rostock University Medical Center, Rostock, Germany
Liver Transpl. 2014 Sep 19

Summary

This case study reports on a 50-year-old immunocompetent woman who was admitted to hospital for acute hepatitis with acute liver failure. After transfer to ICU the patient rapidly developed MOF and was listed for highly urgent liver transplantation. Since existing liver support techniques (MARS® treatment) for bridging while awaiting for liver transplantation had no effect, Single Pass Albumin Dialysis (SPAD) in combination with CytoSorb was applied resulting in a marked decrease of IL-6, bilirubin as well as a reduction of vasopressor need. Orthotopic liver transplantation (OLT) could be successfully performed on the 4th day on ICU. CytoSorb treatment was safe and well-tolerated, without any adverse events occurring. Therefore, CytoSorb seems to be promising and new approach for patients with liver failure.

Case series presentation

- 50-year-old immunocompetent woman was admitted to hospital for acute hepatitis with ALF
- Liver biopsy revealed acute liver cell necrosis due to herpes simplex virus type 1 (HSV-1)
- Despite antiviral therapy liver failure progressed and patient was transferred to ICU
- Rapid development of MOF with hepatic coma, severe coagulopathy, acute anuric renal failure, respiratory insufficiency and arterial hypotension
- Patient was listed for highly urgent liver transplantation
- Additional diagnosis of hemophagocytic lymphohistiocytosis (HLH), secondary to HSV-1-infection
- Hemodialysis and extracorporeal liver support were initiated using MARS® therapy (6 hours 1st day, 19 hours 2nd day)
- Increasing need for NE and excessively elevated concentrations of inflammatory markers indicated ongoing severe SIRS
- Hence extracorporeal therapy was changed to CVVHD with SPAD (12 hours of treatment)

Treatment

- One session of CytoSorb treatment was performed with a treatment duration of 20 hours
- CytoSorb was integrated in a predialyzer position
- Regional anticoagulation was performed using sodium citrate

Measurements

- Need for vasopressors
- IL-6, bilirubin

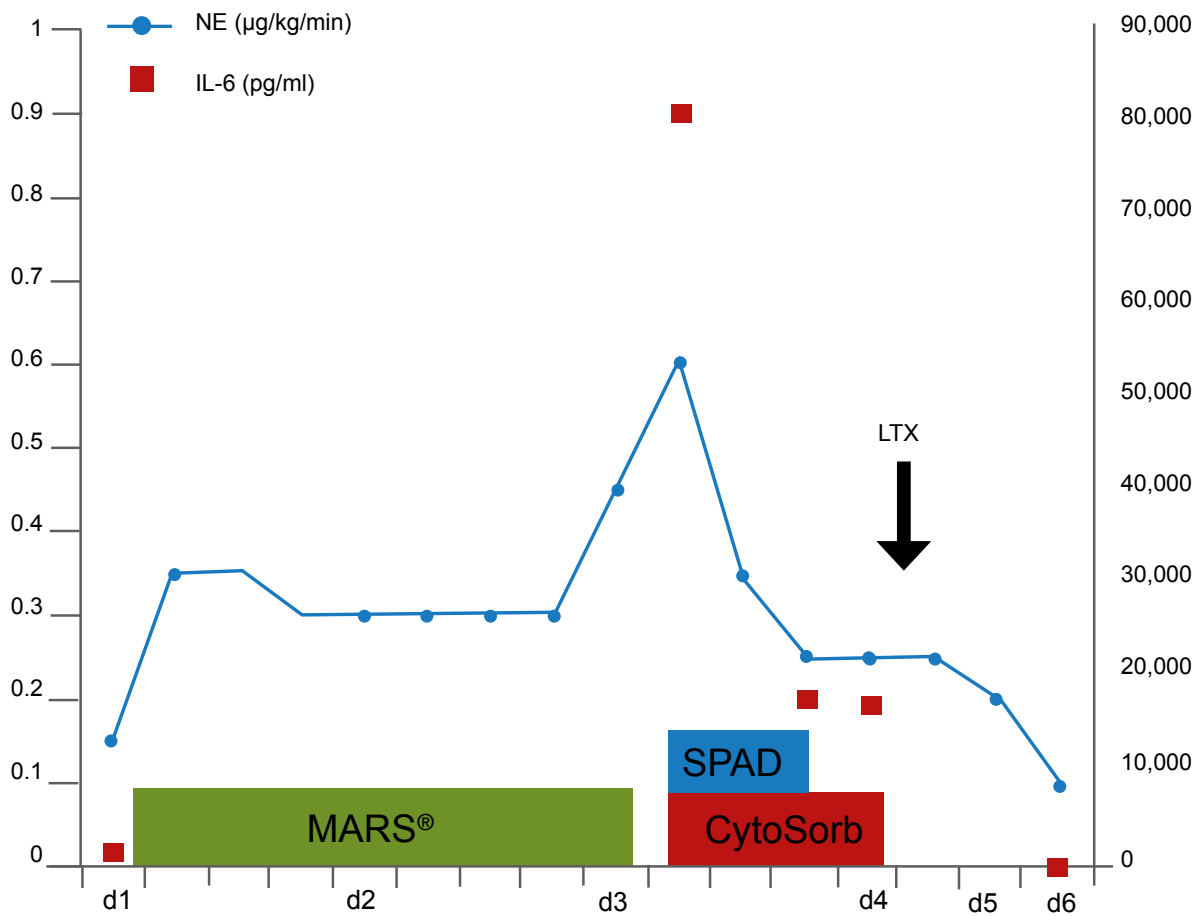
Results

- IL-6 levels fell from 81,059 pg/ml to 17,177 pg/ml after 12 hours of treatment
- Noradrenaline dosage was reduced to 0.25 µg/kg/min
- No further clinical deterioration of the patient
- Antiinfective therapy was conducted with Acyclovir, with no reported adaption of dosage during CytoSorb treatment
- Reduction of the moderately elevated bilirubin with SPAD + CytoSorb

Post-treatment period and follow-up

- Successful OLT on 4th day on ICU
- Further improvement after OLT

Dosage of norepinephrine and plasma levels of IL-6 under therapy



CONCLUSIONS

- First report of the combined use of CytoSorb with SPAD in a patient suffering from ALF and probable HLH with severe SIRS listed for liver transplantation
- Major results of the intervention were a marked decrease of IL-6 and bilirubin, as well as a reduction of vasopressor need
- Treatment was safe and well-tolerated, without any adverse events
- Existing liver support technique (MARS[®] treatment) had no effect on the reduction of bilirubin
- CytoSorb might be a useful tool for patients with acute liver failure and severe hyperinflammatory syndromes

First use of CytoSorb with pruritus – A case report

Bogdanski R

Department of Anesthesiology, Klinikum Rechts der Isar Technical University of Munich, Munich, Germany

Presented at the 1st CytoSorb® - Users' Meeting - Leipzig/Germany 2013

Summary

This case study reports on a 44 year old male patient with pruritus and severe sleep disturbances. Prior medical conditions included primary sclerosing cholangitis with subsequent LTX and reLTX one month later due to primary graft failure. Efforts to treat the pruritus using drugs were unsuccessful. Therefore two treatment attempts were made using CytoSorb. Application of the adsorber resulted in a significant decrease of bilirubin and bile acid plasma levels and a concomitant improvement of the patients' complaints. This is the first case reporting on the use of CytoSorb in the setting of pruritus.

Case presentation

- 44 year old male patient
- Underlying disease: primary sclerosing cholangitis
- LTX in 04/12 and reLTX in 05/12 due to primary graft failure
- Currently new listing for LTX (graft dysfunction)
- Severe itching since 6/2012
- Visual analogue scale (VAS) of 10 with severe sleep disturbances
- Drug treatment attempts by a dermatologist unsuccessful
- Current medications: Prograf, Cellcept, Ursofalk, ASS
- Specific medication for the treatment of pruritus initially rejected
- Decision to use CytoSorb as adjunctive treatment

Treatment

- 2 curative attempts with CytoSorb using a Multi-filtrate® dialysis machine (Fresenius)
- 1st treatment attempt: 5 sessions à 16 hours treatment, heparin anticoagulation, blood flow 120-150 ml/min,
- 2nd attempt: 3 sessions each with 8 hours treatment, confirmed HIT, change to citrate anticoagulation

Measurements

- Bilirubin, bile acids, IL-6, PCT
- Visual analogue scale (VAS)

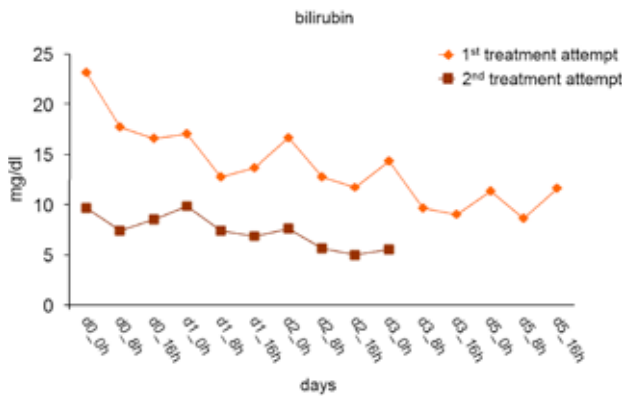
Results

- After 1st treatment attempt (5 x 16 h sessions): Visual analogue scale (VAS) decreased from 10 to 0 for the next 3 weeks
- Before 2nd treatment attempt: VAS of 6-7
- After 2nd treatment attempt (3 x 8 h sessions): VAS of 0 for the next 3 weeks
- Decrease of bilirubin and bile acid plasma concentrations during both treatment attempts
- No change in IL-6 and PCT during the first treatment attempt

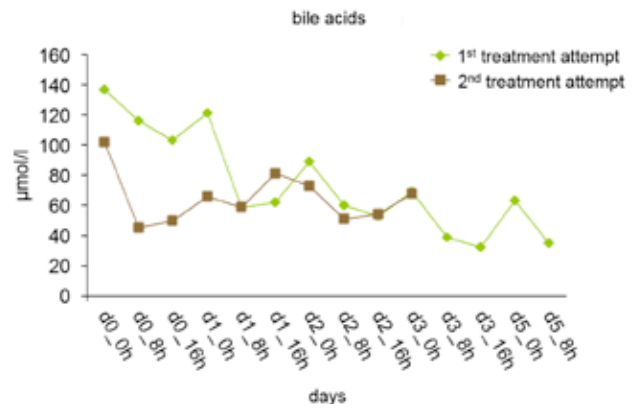
Post-treatment period and follow-up

- After the last CytoSorb treatment change to Prometheus® System (Fresenius) with no further improvement

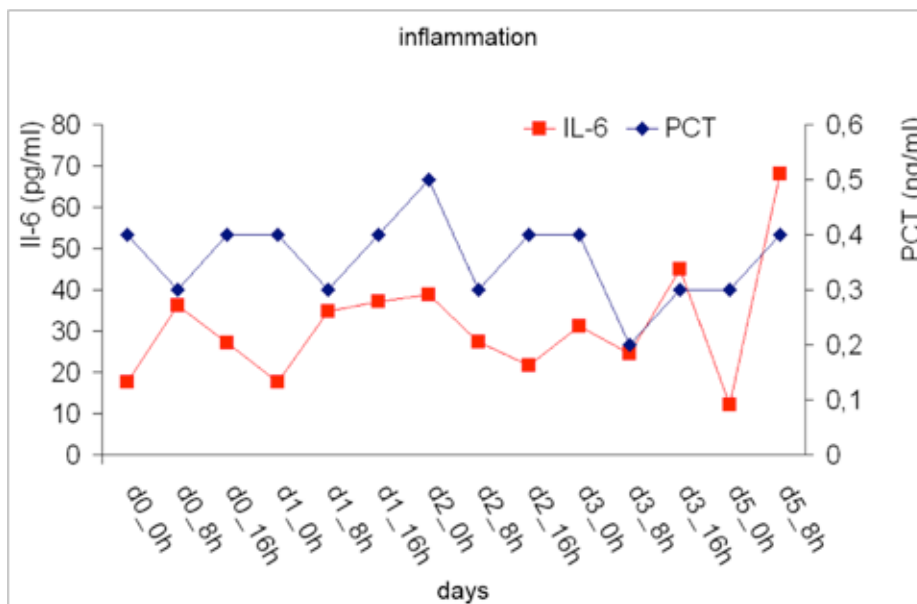
Course of bilirubin during the 1st and 2nd treatment attempt



Course of bile acids during the 1st and 2nd treatment attempt



Course of markers of inflammation (IL-6 and PCT) during the 1st treatment attempt



CONCLUSIONS

- First use of CytoSorb in the setting of pruritus
- Remarkable decrease of plasma bilirubin and bile acid concentrations
- Considerable patient benefit through both treatment attempts, as assessed by a decrease of VAS to 0

Hemoadsorption in Infection - Associated Rhabdomyolysis

Suefke S, Sayk F, Nitschke M
 Medical Clinic 1, University Hospital Luebeck, Germany
Ther Apher Dial. 2016 Mar 17

Summary

This case study reports on a 55-year-old patient with history of arterial hypertension who was admitted with complaints of dyspnea and symptoms of respiratory infection. In the further course the patient developed a fulminant pneumogenic sepsis and acute respiratory distress syndrome (ARDS) with massive requirements for fluids and catecholamines for hemodynamic stabilization. Plasma concentrations of myoglobin and creatine kinase increased drastically on top of his inflammatory response, indicative of massive infection-associated rhabdomyolysis. For treatment of his acute kidney injury grade III (crush kidney) and to lower inflammatory mediator and myoglobin levels, CytoSorb was installed in combination with renal replacement therapy. During the course of the treatment, plasma concentrations of IL-6, procalcitonin, myoglobin and creatine kinase decreased significantly. Levels of leucocytes, thrombocytes, alanine aminotransferase, and aspartate aminotransferase normalized over the 4 consecutive treatments. The clinical situation improved considerably including improvement of the patient's respiratory situation and liver function. The patient was discharged at day 13 with ongoing renal failure and need for renal replacement therapy. In this patient, the application of CytoSorb resulted in a significant reduction of cytokines (i.e. IL-6) but also had an important additive effect on myoglobin removal.

Case presentation

- 55-year-old patient with history of arterial hypertension was admitted with complaints of dyspnea and symptoms of respiratory infection
- Patient developed fulminant pneumogenic sepsis and acute respiratory distress syndrome (ARDS) with massive requirements for fluids and catecholamines for hemodynamic stabilization
- Drastically increased plasma concentrations of myoglobin and creatine kinase on top of his inflammatory response, indicative of massive infection-associated rhabdomyolysis
- Generalized compartment syndrome due to fluid overloading, elevated creatinine levels and acute liver injury as evidenced by hyperbilirubinemia
- For treatment of his acute kidney injury grade III (crush kidney) and for negative fluid balancing, renal replacement therapy was initiated using a Genius device (with an AV600S filter (both Fresenius Medical Care))

- To lower inflammatory mediator and myoglobin levels, CytoSorb was additionally installed

Treatment

- Four consecutive sessions were run over periods of 20 hours each, separated from one another by a pause interval of 4 hours
- Blood flow rates were 150 ml/min
- Anticoagulation was achieved using citrate
- The CytoSorb adsorber was placed in pre-dialyzer position

Measurements

- Laboratory: Myoglobin, creatine kinase, C-reactive protein, IL-6, procalcitonin, creatinine, ALT, AST, bilirubin, leucocytes, thrombocytes, Hct, Hb, albumin, glucose, Na/K
- Clinical: Urine output

Results

- During the course of the treatment, plasma concentrations of IL-6, procalcitonin, myoglobin and creatine kinase decreased significantly
- Levels of leucocytes, thrombocytes, alanine aminotransferase, and aspartate aminotransferase normalized over the 4 consecutive treatments
- The clinical situation improved considerably including improvement of the patient's respiratory situation and liver function
- Kidney function did not improve
- The course of hematocrit, Hb and platelet count provided no evidence for a potential lack of hemo- or biocompatibility of the CytoSorb treatment
- Antibiotic dosages did not have to be adjusted at any time

Markers of inflammation, myoglobinemia, organ (dys)function and blood composition throughout the treatment period

	reference	day 1	day 2	day 3	day 4	day 5	day 6	day 9	day 12
Myoglobin (µg/l)	23-27	30,000	16,982	7,095	4,055	N/A	1,384	921	78
Creatine kinase (U/l)	< 190	22,000	22,000	9,652	6,064	4,021	3,102	2,200	1,950
C-reactive Protein (mg/l)	< 7	87.5	87.5	83.1	93.1	61.6	39.6	29	21
IL-6 (ng/l)	< 5.0	N/A	226.9	173.2	116.6	53.2	32.2	N/A	N/A
Procalcitonin (µg/l)	< 0.05	100	100	56.21	27.74	12.18	5.54	N/A	N/A
Creatinine (µmol/l)	59-104	229	155	128	130	140	150	N/A	N/A
Urine output (ml/day)	> 1,500	< 500	<500	<500	<500	<500	<500	<500	<500
ALT (U/l)	< 50	646	649	587	508	410	347	216	129
AST (U/l)	< 50	1.990	1.905	1.236	821	538	404	294	228
Bilirubin (µmol/l)	2.0 - 21.0	85.1	50.1	35.6	N/A	N/A	12.8	N/A	N/A
Leucocytes (x10 ⁹ /l)	3.9 - 10.2	19.89	22	33.4	29	29	20	13.9	10.1
Thrombocytes (x10 ⁹ /l)	150 - 370	66	84	126	160	184	223	321	229
Hct (%)	39.5 - 50.5	25.5	26.6	24	21.8	22.1	24.1	23.2	25.3
Hb (g/dl)	13.5 - 17.2	8.6	8.9	8.8	8.3	8.1	7.3	7.4	7.9
Albumin (g/l)	35 - 53	19.9	N/A	N/A	25.3	N/A	26.4	N/A	29.5
Glucose (mg/dl)	74 - 106	76	88	102	96	88	87	92	102
Na / K		norm	norm	norm	norm	norm	norm	norm	norm

In total, 4 CytoSorb treatments were performed from day 1 to day 5 in this patient. Samples for data presented in the table were collected immediately after each treatment

Patient follow-up

- Kidney function remained impaired after a total of 5 days on CytoSorb
- Two days after the last treatment with CytoSorb the patient could be extubated without further complications
- Patient was discharged at day 13 with ongoing renal failure and need for renal replacement therapy

CONCLUSIONS

- In this patient, the application of CytoSorb resulted in a significant reduction of cytokines (i.e. IL-6) but also had an important additive effect on myoglobin removal
- The effects seen in this patient are a sum of both adsorption techniques used (CVVH and CytoSorb)
- CytoSorb treatment in this patient proved as safe and free of adverse device-related events. Antibiotic therapy was not adjusted at any time.
- It remains speculative to what extent the effects seen can be ascribed to the application of the CytoSorb adsorber and therefore needs to be investigated in future randomized controlled trials

CytoSorb in a patient with legionella-pneumonia associated rhabdomyolysis

Wiegele M, Krenn CG.

Clinical Division of Anesthesiology and General Intensive Care Medicine Department of Anesthesia, General Intensive Care and Pain Control, Medical University of Vienna, Austria

ASAIO J. 2015 Jan 29

Summary

This case study reports on a 44-year-old man presenting with ongoing fever and impaired general condition for more than 5 days. Respiratory insufficiency finally led to hospitalization and rapid admission to an intensive care unit with intubation and ventilatory support. Chest x-ray and computed tomography confirmed the clinical diagnosis of ARDS. Investigation of patient's specimen further revealed infection with legionella pneumophila. Despite administration of antibiotics, liver enzymes and parameters of renal function deteriorated in parallel within the following days, indicating a trend toward multiple organ failure. Creatine kinase and myoglobin levels increased in combination with reduced urine excretion. Therefore CytoSorb treatment was started in hemoperfusion-mode (stand-alone application form) on day 6 after admission. Within 8 hours, myoglobin levels decreased from 18,390 to 10,020 ng/ml and in a second cycle again declined from 13,400 to 8,359 ng/ml. The patient's condition improved subsequently. Renal function completely recovered and hemodialysis was not necessary at any time of hospitalization. No side effects of therapy have been observed in this patient. This is the first time that a decrease of myoglobin levels following application of CytoSorb cartridge could be demonstrated in vivo.

Case series presentation

- 44-year-old man presented with ongoing fever and impaired general condition for more than 5 days
- Admission to ICU after clinical diagnosis for acute respiratory distress syndrome (ARDS) with proven infection from legionella pneumophila
- Despite administration of antibiotics, liver enzymes and parameters of renal function deteriorated in parallel within the following days, indicating a trend towards multiple organ failure
- Despite adequate fluid administration right from the beginning, creatine kinase and myoglobin levels increased in combination with reduced urine excretion

Treatment

- 2 sessions were run on 2 consecutive days (day 6 and 7 after admission) for 5-6 hours each
- CytoSorb was run on a multiFiltrate® (Fresenius) in hemoperfusion-mode (stand-alone mode)
- Blood flow rates were 300 ml/min
- Enoxaparin was administered subcutaneously to prevent thromboembolic events but no additional anticoagulant was added to the extracorporeal system

Measurements

- Myoglobin levels, noradrenaline
- Markers for renal function – i.e. creatinine, blood urea nitrogen, urine output
- Markers for liver function (bilirubin, overall protein, albumin, ASAT, ALAT, yGT, LDH)

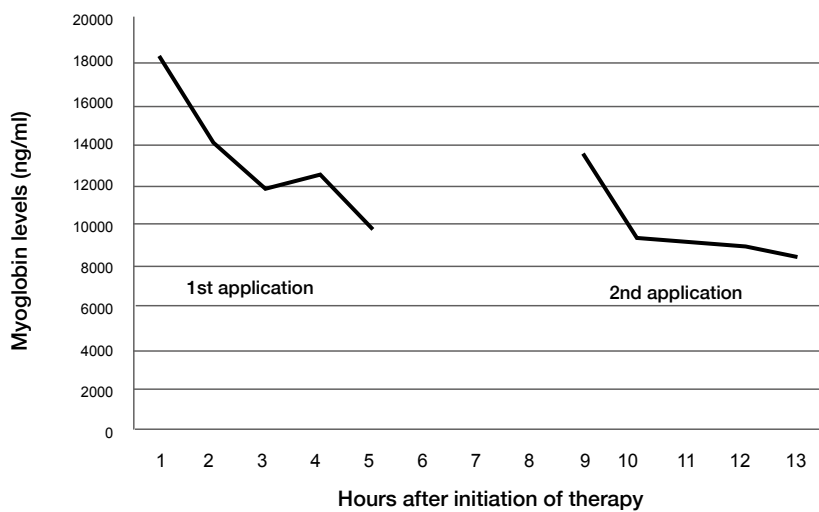
Results

- Decrease of myoglobin levels from 18,390 ng/ml to 10,020 ng/ml within 8 h
- Further decline from 13,400 ng/ml to 8,359 ng/ml during the second cycle on day 7
- Parameters of renal function and liver enzymes improved within hours and subsequently during the next days
- In parallel the patient's urine output increased from < 0.5 ml/kg/h to >1 ml/kg/h
- No side effects of therapy have been observed

Post-treatment period and follow-up

- The patient's condition improved subsequently
- Renal function completely recovered and hemodialysis was not necessary at any time of hospitalization
- Finally the patient was transferred to a normal ward on day 22

Myoglobin levels during hemoperfusion with CytoSorb (1st run: 0-6 hours, 2nd run: 9-14 hours)



Course of standard laboratory markers and myoglobin levels during intensive care unit stay

CytoSorb 1st application - CytoSorb 2nd application

Length of ICU stay	Days	1	5	6	7	8	8	8	8	15	22
	Time				20:39:59	04:37:53	07:07:13	12:44:11	21:10:11		
Creatinine	mg/dl	1.25	1.21	1.07	1.56	1.09	1.06	1.04	1.15	0.45	0.34
Blood urea nitrogen	mg/dl	15	54.2	51	74.6	71.2	70.4	72.7	78.1	18.8	9.8
Bilirubin	mg/dl	4.98	1.94	1.52	1.57	1.44	1.4	1.4	0.94	0.73	0.66
Overall protein	g/l	51.2	51.7	57.6	57.7	56.7	57.5	58.4	53.7	53.3	52.8
Albumin	g/l	19.9	25.1	24.1	25.5	24.2	25.7	25.2	23.9	27.5	30.3
ASAT (GOT)	U/l	149	106	161	440	462	456	395	285	113	20
ALAT (GPT)	U/l	71	40	38	120	138	141	137	121	163	57
Gamma - GT	U/l	44	124	244	764	873	897	864	853	738	343
Myoglobin	ng/ml			7,066	18,390	10,020	9,173	13,400	8,359	387	
LDH	U/l	413	342	429	629	712	620	529	430	315	214
Urine output	ml/kg/6h				0.25				2.44		
Noradrenaline	mcg/kg/min	0.309	0.02	0.103	0.144	0.137	0.103	0.12	0.10		

CONCLUSIONS

- First time that a decrease of myoglobin levels following application of CytoSorb cartridge could be demonstrated in vivo
- After commencement of CytoSorb treatment, the patient's condition improved subsequently and renal function completely recovered. Renal replacement therapy could be avoided.
- No adverse or any device-related side effects were documented during or after the treatment sessions
- Whether application of CytoSorb prevents acute renal failure necessitating hemodialysis in patients with rhabdomyolysis in any case remains to be investigated in randomized controlled trials

SIRS and Sepsis - REGAIN CONTROL



CytoSorbents Europe GmbH

office +49 (0)30 654 99 145 | fax +49 (0)30 654 99 146 | e-mail: support@cytosorbents.com
Müggelseedamm 131, 12587 Berlin, Germany

www.cytosorb.com